

**UNIVERSITY OF MEDICINE AND PHARMACY OF
CRAIOVA**

DOCTORAL SCHOOL

Doctorate thesis

Abstract

**Histological aspects of photodynamic
therapy in dermatology**

Scientific coordinator,

Professor Laurențiu Mogoantă MD, PhD

PhD student,

Radu Constantin Cătălin

Craiova

2013

Introduction

The cancer remains a major public health problem. The morbidity of cancer had an impressive growth in the recent decades and, in this context, skin carcinoma's incidence increased in the U.S., Canada, Europe and Australia by 4-8 % per year. The incidence of melanoma has doubled every 10 years in the countries with white populations. In 2007, in the whole world were diagnosed 12 million new cases of cancer, 20% of them with cutaneous localization. Skin cancer represents about 6% of skin diseases, their most important features is that they often develops on precancerous lesions, early diagnosis and treatment prevents malignant transformation, their locations, their polymorphic clinical and histological aspects allow an early diagnosis and the use of a broad therapeutic range. Among the therapeutic means of skin cancer, a non invasive method was developed, having satisfactory clinical results. Already included in current treatment guidelines and addressing many skin problems, this new treatment is gaining ground. Photodynamic therapy (PDT) is a non- invasive therapeutic method with applications in dermatology, which involves three key elements (a photosensitiser, light and the oxygen in a tissue) and is conducted in two stages. The first stage involves the preferential uptake and accumulation of photodynamic active porphyrins in the target tissue and the second stage involves illumination with a light source, with a suitable wavelength, producing therapeutic effect.

There have been published numerous studies, therapeutic trials, also raised the issue of a more clear, standardized method. In addition to the need for identifying the perfect treatment protocol, to establish those elements that constitute the microscopic substrate of photodynamic therapy, still remains an elusive goal. This paper aims to nominate some of these items. Keywords: cancer, premalignant and malignant skin disorders, photodynamic therapy, delta-aminolevulinic acid

PART I. GENERAL DATA

Chapter 1. The ontogenesis and histology of the skin, presents recent data about the anatomy, embryology, development and differentiation of the skin. The next are presented the defining elements of skin histology, epidermis, dermis and hypodermis, in detail the skin cellularity. This chapter ends with skin annexes, cutaneous innervation and vasculature.

Chapter 2. Skin Carcinogenesis - Risk Factors. This section lists the main factors contributing to the emergence of cutaneous neoplasia and the skin carcinogenesis stages. There are references to the involvement of intrinsic genetic oncogenes, proto-oncogenes, growth factors and suppressor genes. The next are presented the extrinsic factors. In completing this chapter we discussed the photocarcinogenicity, outlining the role of solar radiation in carcinogenesis. Finally

are presented the mechanical factors and smoking, extrinsic factors that have a known carcinogenic potential.

Chapter 3 presents the detailed morphology of basal cell carcinomas (BCC). Below are listed the most common clinical forms. Microscopic aspects of BCC are described further, their characters and the most common species. The squamous cell carcinomas (SCC) are listed, their clinical and histological aspects, without forgetting the description of actinic keratoses, considered premalignant skin lesions, whose outcomes may be complicated by the development of squamous cell carcinoma.

There were brought to attention the immunohistochemical aspects of basal cell and squamous cell carcinomas, the present work not only watching on histological changes induced by photodynamic therapy, but also on immunohistochemical changes occurring post-treatment.

PART II. PERSONAL CONTRIBUTIONS

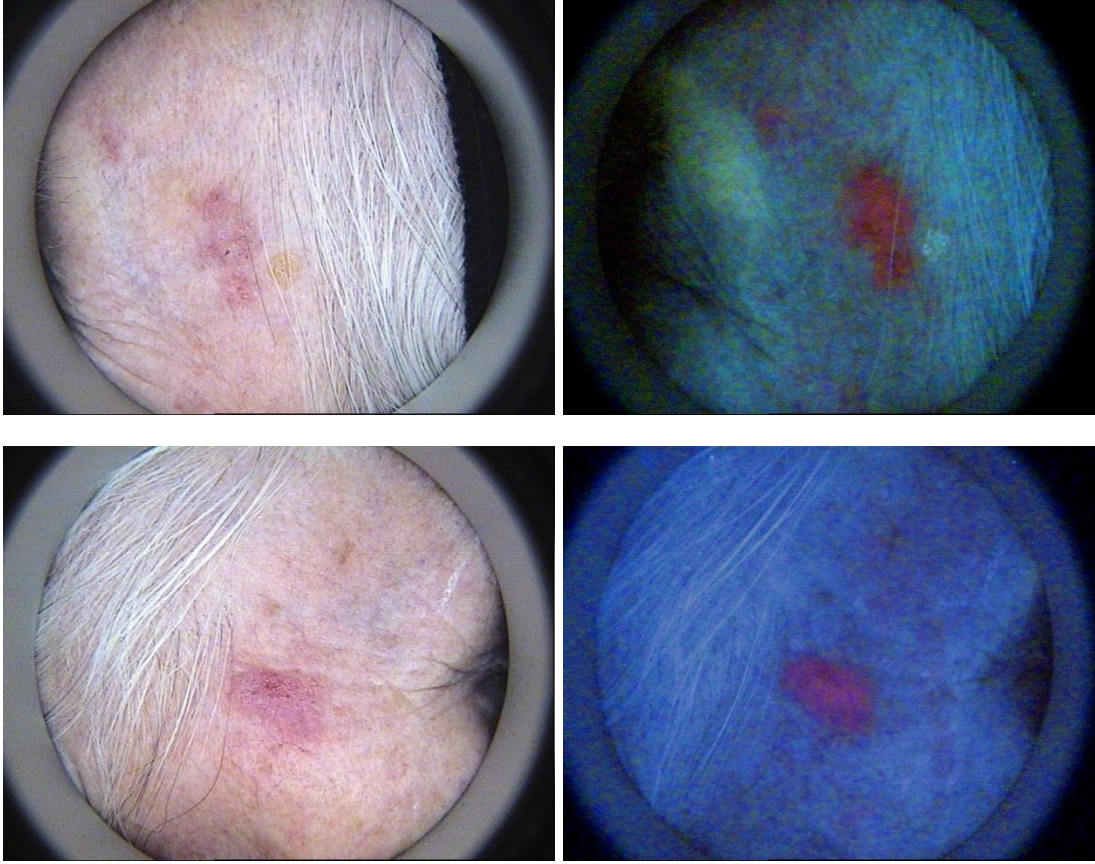
Chapter 4 begins with the presentation of the therapeutic method which is the subject of this paper, the photodynamic therapy (PDT). Initially are presented historical data, several scientists attempts to treat, using photodynamic therapy, various dermatological conditions. Below was explained the photodynamic mechanism. PDT involves light activation of a photosensitizer in the presence of an oxygen rich environment. There are used as photosensitizers the delta- amino levulinic acid (ALA) or its methyl ester (MAL), applied topically to skin lesions for various periods of time, which leads to the conversion of ALA into protoporphyrin IX, endogenous photo-activating agent. Protoporphyrin IX accumulates in target tissues, tissues with rapidly proliferating cells, superficial basal cell carcinoma, in situ squamous cell carcinoma or their precursors, actinic keratoses. After activation by a light source in the presence of oxygen , the sensitizer (protoporphyrin IX) is oxidized , which results in generating of reactive oxygen species, the process continues with the selective destruction of excited cells (induction of apoptosis or necrosis), without affecting the surrounding tissue.

Chapter 5 describes the methodology of our study. We performed a retrospective study on 30 patients treated in the dermatologic Practice Ionescu-Borcea, Geldern, Germany. For each patient included in the study we retained identification data (name, sex, age), origin, profession, medical history, clinical and histological diagnosis.

Treatment Protocol

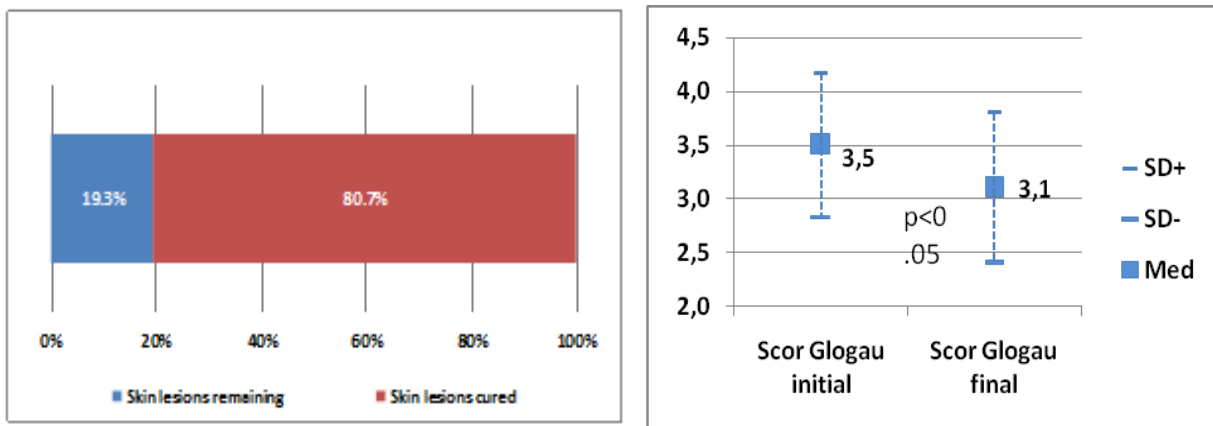
Within 30 days, we performed two sessions of photodynamic therapy, comprising in applying on the skin of photosensitizers - delta-aminolevulinic acid 20% cream under occlusive dressing for four hours.

The illumination was conducted with red light, the wavelength specified by the manufacturer with a peak at 630 nm (PhotoDyn®750, Heine.Med GmbH&Co. KG, Germany) with a total light dose of 37 J cm⁻², for 12 to 15 minutes.



Spinalioma in situ, clinical aspect and photo-dynamic diagnosis using FotoFinder

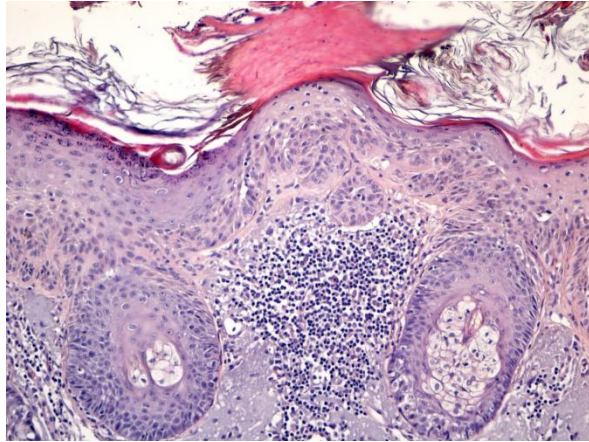
Chapter 6. Results. Clinical evaluation: the total number of treated lesions was 238. Clinical success was observed in 192 lesions, the percentage of clinical response was approx. 81%. The improvement in photodamaged skin, as assessment of treatment success, we evaluated on the Glogau Scale.



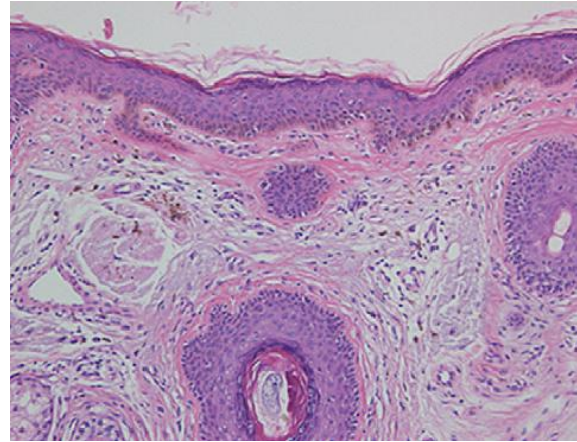
Therapeutic succes: 80% of the skin lesions were cured, improvement in the photodamaged skin, quantified on the Glogau Scale, before and after

The patients were scored for global photoageing, mottled pigmentation, facial erythema, telangiectasias and coarse wrinkles.

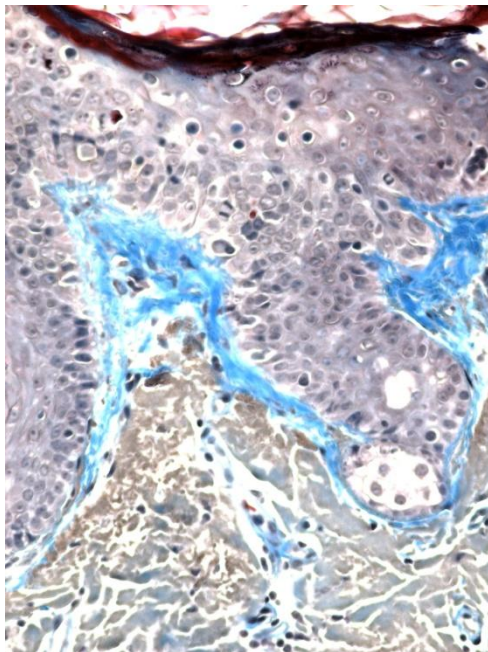
Histological and immunohistochemical findings



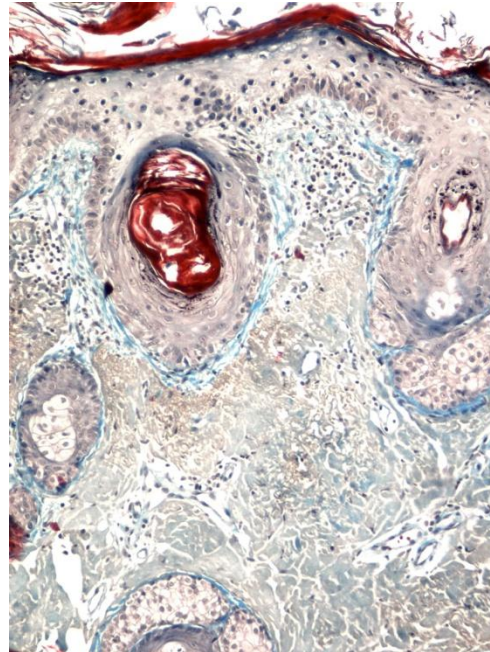
Actinic keratosis before PDT



Actinic keratosis after PDT Col. HE x40



Before PDT: collagen fibers

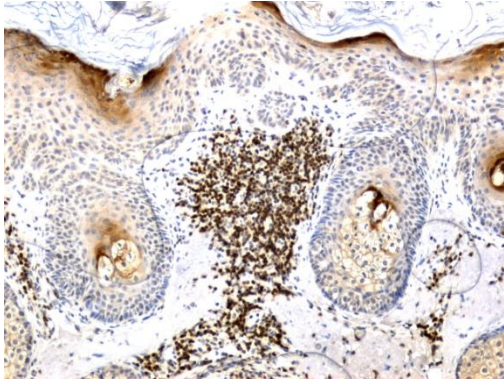


**After PDT: normalized
disposition of collagen fibers**

Col. Trichromic Goldner Szekely, X20

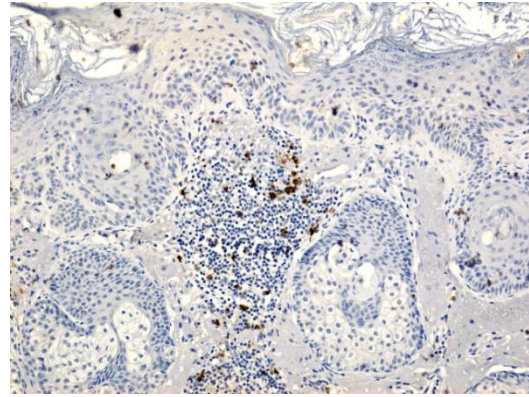
For a better differentiation of the cells discovered in the inflammatory infiltrate, we used several specific antibodies: CD3 for T lymphocytes, CD20 for B lymphocytes, CD68 for the

study of macrophages, CD34 for showing the angiogenesis in the inflammatory infiltrate, as following.



Focal inflammatory infiltrate with T lymphocytes CD3 +

Actinic keratosis X10



Inflammatory infiltrate with rare B lymphocytes CD20 +

Actinic keratosis X10

Chapter 7. Discussions. Photodynamic therapy is regarded as one of the reference therapies for the treatment of actinic keratoses, superficial skin carcinomas and chronic photoexposed skin. Also seen as a therapeutic approach even to the treatment of large skin areas, photodynamic therapy is a noninvasive method with excellent results.

There are currently numerous clinical trials comparing PDT with traditional therapeutic techniques (surgery, cryotherapy, topical chemotherapy), studies whose results are more than promising. Szeimies et al. [1] compared the results of surgical treatment of superficial basal cell carcinomas with those of PDT, a study on 196 patients. Clinical success rate at 3 months was 92.2% (PDT) vs. 99.2% (surgery). At 12 months there was a recurrence rate of 9.4% in the photodynamic treated malignant lesions and no recurrence after surgery.

Using a different lighting scheme applied to premalignant skin lesions, carcinomas in situ and superficial basal cell carcinomas, de Haas et al. [2] published similar results: a follow-up of 12-24 months, registered clinical success in superficial basal cell carcinomas by 97%, for 98% of actinic keratoses, Morbus Bowen for only 84%.

The histology explains the results of therapy, also its limitations. There are studies that investigate the histological changes induced by PDT [3], [4]. A recent study examining histological changes [5], suggested that apoptosis occurs one day after performing PDT. An infiltrate of lymphocytes and neutrophils were observed in the upper layer of the dermis. One day after PDT, all epidermal layers exhibit a slightly degenerative necrosis with shadow cell formation and chromatin condensation around the nuclear membrane in the lower layer of the epidermis. Necrosis was observed in all layers of the epidermis and infiltration of lymphocytes three days after PDT. Tumor cells have disappeared and a thickening of the epidermis was observed seven days after PDT.

Bagazgoitia et al. [6] describes a decrease of cellular dysplasia and elastosis and reduction of Ki-67 and p53 expression in skin samples taken six weeks after PDT, while the expression of cyclin D1 remained stable. The authors' observations show that PDT reduces histological signs

of cutaneous aging process, while the reduction of expression of tumor markers indicates a reversible process of carcinogenesis.

Reducing solar elastosis and improving overall skin appearance post-treatment can be explained by the effect of PDT on collagen.

We are also reminding an *in vitro* study conducted by S. Karrer et al. [7], in which patients with localized scleroderma receiving 5 aminolevulinic acid photodynamic therapy show a reduction in the infiltration of the skin, suggesting that this therapy reduces skin sclerosis. The effects of PDT on collagen metabolism were also studied. Normal and scleroderma fibroblasts were treated with sub-lethal doses of 5 aminolevulinic acid and red light. The results showed that 5 aminolevulinic acid induced expression of matrix-metalloproteinases 1 and 3 (MMP) in normal fibroblasts and scleroderma, while reducing the expression of mRNA of the type I collagen. The induction of collagen degradation enzymes together with reduced collagen production can be responsible for the anti-sclerosis effect of photodynamic therapy observed *in vivo*.

In a subsequent study [8], the same authors treated keratinocytes *in vitro* with sublethal doses of 5 aminolevulinic acid, in which environment, human fibroblasts were exposed. The result: treated fibroblasts showed an increased induction to 3 times of the MMP 1 and 3 levels, suggesting that photodynamic therapy modulate the MMP 1 and 3 through indirect mechanisms. The RNAm expression of collagen type I was not significantly altered.

Chapter 8. Conclusions.

1. This paper addresses a current topic of great interest, located on the border between histology, physiology, dermatology, surgery, having a particular importance in a large number of cases, with a debilitating potential. Skin cancer is a serious public health problem.
2. The study followed the clinical response of photodynamic therapy, its efficiency in premalignant and malignant skin lesions, the improving in the appearance of skin in patients with chronic photo-exposed skin and photo-aging.
3. Skin samples were taken from the patients, in which the clinical response was not the one expected, following histological and immunohistochemical researches, which helped to a better understanding of the therapy at a cellular level.
4. Histological findings of this study provide evidence showing the beneficial effects of photodynamic therapy on chronic photo-exposed skin, photo -aging.
5. Histological and immunohistochemical analyzes indicate a decrease in the degree of severity and extension keratinocyte atypia, associated with a filing with dermal collagen, improving of solar elastosis in those skin areas which are affected by field- cancerisation.
6. These data suggest that photodynamic therapy is efficient in treating malignant and pre-malignant skin lesions, may decrease the carcinogenic potential in areas with field- cancerisation and cause a partial reversal of skin aging.

Bibliography

1. RM Szeimies, S Ibbotson, DF Murell, D Rubel, Y Frambach, D de Berker, R Dummer, N Kerrouche, H Villemagne, A clinical study comparing methyl aminolevulinate photodynamic therapy and surgery in small superficial basal cell carcinoma (8-20 mm), with a 12-month follow-up, *JEADV* 2008, 22
2. ERM de Haas, HC de Vijlder, HJCM Sterenborg, HAM Neuman, DJ Robinson, Fractionated aminolevulinic acid-photodynamic therapy provides additional evidence for the use of PDT for non-melanoma skin cancer, *JEADV* 2008, 22
3. Photorejuvenation induced by 5-aminolevulinic acid photodynamic therapy in patients with actinic keratosis: a histologic analysis. Park MY, Sohn S, Lee ES, Kim YC. *J Am Acad Dermatol.* 2010 Jan;62(1):85-95. Epub 2009 Nov 18.
4. Clinical, histopathological and immunohistochemical assessment of human skin field cancerization before and after photodynamic therapy. Szeimies RM, Torezan L, Niwa A, Valente N, Unger P, Kohl E, Schreml S, Babilas P, Karrer S, Festa-Neto C. *Br J Dermatol.* 2012 Jul;167(1):150-9. doi: 10.1111/j.1365-2133.2012.10887.x. Epub 2012 Jun 1
5. Nakaseko H, Kobayashi M, Akita Y, Tamada Y, Matsumoto Y., Histological changes and involvement of apoptosis after photodynamic therapy for actinic keratoses. *Br J Dermatol.* 2003 Jan;148(1):122-7
6. Bagazgoitia L, Cuevas Santos J, Juarranz A, Jaen P. Photodynamic therapy reduces the histological features of actinic damage and the expression of early oncogenic markers. *Br J Dermatol* 2011;165:144–51.
7. Karrer S, Bosserhoff AK, Weiderer P, Landthaler M, Szeimies RM., Influence of 5-aminolevulinic acid and red light on collagen metabolism of human dermal fibroblasts *J Invest Dermatol.* 2003 Feb;120(2):325-31.
8. Karrer S, Bosserhoff AK, Weiderer P, Landthaler M, Szeimies RM , Keratinocyte-derived cytokines after photodynamic therapy and their paracrine induction of matrix metalloproteinases in fibroblasts., *Br J Dermatol.* 2004 Oct;151(4):776-83