
**UNIVERSITY OF MEDICINE AND PHARMACY
CRAIOVA
DOCTORAL SCHOOL**

**PhD
THESIS**

**CONTRIBUTIONS TO THE STUDY
OF THE CLINICAL-MORPHOLOGICAL
PROFILE OF CEREBRAL HAEMORRHAGE
-ABSTRACT-**

Scientific Coordinator:
Professor Iancu Emil PLEȘEA

PhD Student:
Carmen Corina STANCU

2013

TABLE OF CONTENTS

C O N T E N T S	I
A B B R E V I A T I O N S	VI
I N T R O D U C T I O N	1
B A C K G R O U N D	4
C H A P T E R I B R A I N M O R P H O L O G Y E L E M E N T S	5
CEREBRAL VASCULARIZATION	6
<i>Arterial vascularization</i>	6
<i>Cerebral Venous System</i>	27
NEUROVASCULAR UNIT	33
<i>Overview</i>	33
<i>Anatomical description</i>	34
<i>Alteration of Junction</i>	40
CEREBROSPINAL FLUID SPACES	41
<i>Spaces arising from primitive neural tube</i>	41
<i>Subarachnoid space</i>	44
C H A P T E R I I C E R E B R A L H A E M O R R A G E ..	47
I N T R O D U C T I O N	48
D E F I N I T I O N A N D C L A S S I F I C A T I O N	48
E P I D E M I O L O G Y	49
R I S K F A C T O R S	49
<i>Modifiable risk factors</i>	49
<i>Non - modifiable risk factors</i>	50
A E T I O L O G Y	51
<i>Hypertension</i>	51
<i>Amyloid angiopathy</i>	52
<i>Vascular malformations</i>	52
T R I G G E R S	55
<i>Endogenous triggers</i>	55
<i>Exogenous triggers</i>	55
P A T H O G E N E S I S	56
<i>Hematoma formation</i>	56
P A T H O L O G Y	57
<i>Localisation</i>	57
<i>Other macroscopic aspects of ICH</i>	60
C L I N I C A L F E A T U R E S O F I C H	66
<i>Clinical assessment scales</i>	67
I M A G I N G I N V E S T I G A T I O N S	69
<i>Native Computed Tomography</i>	69
<i>Computed Tomography Angiography</i>	69
<i>Magnetic Resonance Imaging</i>	70
N E W T H E R A P E U T I C T R E N D S	70
E V O L U T I O N A N D P R O G N O S I S	72
I C H P R O P H I L A X Y	73

PERSONAL CONTRIBUTION.....	74
CHAPTER III MATERIAL AND METHODS.....	75
MATERIALS.....	76
<i>Inclusion criteria</i>	76
<i>Study groups</i>	77
<i>Data sources</i>	78
METHODS	78
<i>Type of study</i>	78
<i>Aim of study</i>	78
<i>Parameters</i>	79
<i>Acquisition of microscopic images</i>	85
<i>Statistical analysis</i>	85
<i>Scales of parameter stratification</i>	86
CHAPTER IV CLINICAL STUDY	91
CEREBRAL HAEMORRHAGE STATISTICS WORLDWIDE	92
TEMPORAL DISTRIBUTION.....	93
<i>Annual variation</i>	93
<i>Monthly variation</i>	94
<i>Seasonal Variation</i>	95
GENDER.....	96
SOCIAL ENVIRONMENT.....	97
AGE GROUPS.....	98
HYPERTENSION SEVERITY.....	100
OTHER RISK FACTORS	101
IMPAIRMENT OF CONSCIOUSNESS.....	103
STROKE SEVERITY	104
<i>NIHSS score at admission</i>	104
<i>NIHSS score at discharge</i>	105
THROMBOEMBOLIC EVENTS.....	107
TYPE OF DISCHARGE	109
LENGTH OF STAY	110
FINAL COMMENTS ON THE CLINICAL STUDY	112
CHAPTER V MORPHOLOGICAL STUDY	114
MACROSCOPIC STUDY	115
<i>Hemorrhagic foci topography</i>	115
<i>Deep Intracerebral Hemorrhage</i>	118
<i>Lobar Intracerebral Hemorrhage</i>	123
<i>Brainstem and cerebellar hemorrhage</i>	130
<i>Dimensions of hemorrhagic foci</i>	132
<i>Intraventricular haemorrhage and subarachnoid effusion</i>	148
<i>Perilesional edema and mass effect</i>	150
MORPHOLOGICAL STUDY OF VESSEL WALL CHANGES.....	153
<i>Overview</i>	153
<i>Perilesional edema</i>	159
<i>Microbleeds presence</i>	161
<i>Changes of the large arteries wall</i>	163
<i>Changes of the penetrant arteries and arterioles wall</i>	168
<i>Capillary changes</i>	172

<i>Genesis of hemorrhagic foci</i>	177
FINAL COMMENTS ON THE MORPHOLOGICAL STUDY	178
CHAPTER VI CLINICAL – MORPHOLOGICAL	
CORRELATIONS	183
PROGNOSTIC IMPACT OF THERAPY	184
DISCHARGE STATUS – AGE	185
DISCHARGE STATUS – HYPERTENSION.....	186
DISCHARGE STATUS – GCS SCORE	186
DISCHARGE STATUS – NIHSS SCORE	187
DISCHARGE STATUS – LENGTH OF HOSPITALISATION	188
DISCHARGE STATUS – THROMBOEMBOLIC EVENTS	189
DISCHARGE STATUS – HEMATOMA TOPOGRAPHY	190
DISCHARGE STATUS – HEMATOMA VOLUME	191
DISCHARGE STATUS – INTRAVENTRICULAR HEMORRHAGE	192
DISCHARGE STATUS – SUBARACHNOID EFFUSION	192
HEMATOMA TOPOGRAPHY – AGE	193
HEMATOMA TOPOGRAPHY – HYPERTENSION	194
HEMATOMA TOPOGRAPHY – GCS SCORE.....	195
HEMATOMA TOPOGRAPHY – NIHSS SCORE	196
HEMATOMA TOPOGRAPHY – INTRAVENTRICULAR HEMORRHAGE	197
HEMATOMA TOPOGRAPHY – LENGTH OF HOSPITALISATION	198
HEMATOMA VOLUME – HYPERTENSION	199
HEMATOMA VOLUME - GCS SCORE	200
HEMATOMA VOLUME – NIHSS SCORE	201
HEMATOMA VOLUME - INTRAVENTRICULAR HEMORRHAGE	201
INTRAVENTRICULAR HEMORRHAGE – HYPERTENSION	202
INTRAVENTRICULAR HEMORRHAGE – GCS SCORE	203
INTRAVENTRICULAR HEMORRHAGE – NIHSS SCORE	204
FINAL COMMENTS ON THE CLINICAL - MORPHOLOGICAL CORRELATIONS STUDY	205
CONCLUSIONS	207
REFERENCES	210
LITERATURE REFERENCES.....	211
PERSONAL REFERENCES.....	233

ABBREVIATIONS

ACA	Anterior cerebral artery
ACC	Common carotid artery
AchA	Anterior choroidal artery
ACI	Internal carotid artery
ACM	Middle cerebral artery
ACoA	Anterior communicating artery
ACoP	Posterior communicating artery
ACP	Posterior cerebral artery
ACS	Superior cerebellar artery
AICA	Anterior - Inferior cerebellar artery
AIT	Transient ischemic attack
AngioCT	Computer Tomography Angiography
AVC	Stroke
BHE	Blood-brain barrier
CT	Computer Tomography
DZ	Diabetes
ECG	Electrocardiogram
GSC	Glasgow Coma Scale
HE	Hematoxylin – Eosin
HIC	Intracranial hypertension
HSA	Subarachnoid hemorrhage
HTA	Hypertension
HVS	Left ventricular hypertrophy
ICH	Intracerebral hemorrhage
IHC	Immunohistochemistry
IMA	Acute Myocardial Infarction
IV	Intraventricular
LCR	Cerebrospinal fluid
MAV	Arteriovenous malformation
NIHSS	National Institutes of Health Stroke Scale
OMS	World Health Organization
PICA	Posterior - Inferior cerebellar artery
rFVIIa	Recombinant activated factor VII
RMN	Magnetic resonance imaging
TA	Blood pressure
TEPA	Pulmonary thromboembolism
Tn T	Troponin T
TVP	Deep vein thrombosis
VSH	Erythrocyte sedimentation rate

KEY WORDS:

Intracerebral haemorrhage, hemostatic therapy, hematoma volume

INTRODUCTION

The cerebral haemorrhage (ICH) is a devastating form of stroke, representing one of the main cause of death nowadays. It has a major impact on the public health not only by its enormous costs of the hospitalization and the patient management but also by productivity reduction, the cerebral haemorrhage being an impairment that outruns severe disability (Earnshaw et al., 2006).

By its ethiopathogenic and topographic features, the cerebral haemorrhage imposes a personalised treatment, sometimes with neurosurgical possibilities some other time a strict conservative treatment.

Paradoxically, in spite of the fact that the percentage of the hospitalized patients with cerebral haemorrhage has increased lately, there hasn't been registred simultaneously any reduction of the mortality (Lloyd -Jones et al., 2010).

This aspect is probably due to the lack of any specific medication treatment.

If until this present thesis there isn't any hope to have a drug therapy able to determine the rapid resorption of haemorrhage, there is the real possibility of a therapy that aims at a frightening precious complication, that is the hematoma expansion: recombinant activated Factor VII therapy.

Recombinant activated Factor VII or eptacog alpha is a protein got from genetic engineering, structurally and functionally similar to Factor VII from human plasma, destined initially to the therapy of haemophilic patients.

This use in neurology and neurosurgery has generated various controversials for some time. It arrest ongoing bleeding but it also has thromboembolic side effects, it doesn't improve long-term prognosis at all patients and the therapy is very expensive , according to some clinicians.

The researchers agreed with the necessity of careful selection based on pre-established criteria of the patients candidates for this kind of therapy and also the reconsidering position regarding the effective therapy dose.

Monotherapy with rFVIIa has already been tested in several clinical trials (Mayer et al. 2005 , 2008).

The studies achieved recently as well as the ones ongoing in the world, have already identified the selection potential criteria of the patients by adding to the well-known clinical and biological criteria, a new paraclinic criterion: biomarker "spot sign" highlighted by the examination of the Computer Tomography Angiography (Demchuk et al., 2012).

On the other hand there are discovered new properties to the vitamin K: vasoprotective, neuroprotective and modulatory proprieties through the dependent proteins of the stem cells proliferation at the level of the subventricular niche and constitutes a necessity to some patients with aquired Factor VII deficiency (Gely - Pernot et al., 2012; Chou, Inks & Josey, 2013).

Taking into consideration these aspects as well as the fact that I haven't found information in the Romanian literature related to the morphological study of cerebral haemorrhage according to the treatment, particularly the one treated with rFVIIa and Vitamin K, I proposed myself to approach this subject.

Thus, the present thesis tries to be a modest contribution to the understanding of this redoubtable disease.

STATE OF KNOWLEDGE

In the first part of the paper consisting of two chapters, I have tried to outline a formal introduction and a review regarding the elements of brain morphology on one hand and on the other hand, a detailed description of the latest data regarding the epidemiology , etiology, pathogenesis, diagnosis and treatment of cerebral hemorrhage.

PERSONAL CONTRIBUTION

The second part of the paper, representing personal contribution is divided into four main chapters linked in a classical sequence of a research project.

In the first chapter, we defined the study material , described the research methodology that we used, including parameter stratification scales , the algorithm of brain hemorrhage morphological investigation, both macroscopic and microscopic evaluation and use of computerized quantitative analysis for some of the parameters.

STUDY DESIGN

The study was conducted in two main directions

- a retrospective analysis that targeted the cases hospitalized and diagnosed in 2008
- a prospective analysis that included patients newly admitted during the period of the PhD, from 2009 to 2012

AIM OF STUDY

- Assessment of hematoma behavior under different therapeutic protocols
- Identification of the mechanism that led to death by means of necropsy

MATERIAL AND METHODS

Based study consisted of 720 patients diagnosed with spontaneous intracerebral hemorrhage , admitted to the Department of Neurology from Emergency County Hospital of Slatina, during 2008-2012 .

Patients with spontaneous intracerebral hemorrhage documented by brain Computer Tomography examination performed at the admission were considered potentially eligible.

The distribution of patients in the study groups was performed according to the treatment protocol that was applied (Figure 1).

This afforded three study groups :

- ⇒ **Group A** 319 cases that did not receive hemostatic treatment
- ⇒ **Group B** 361 cases treated with standard doses of conventional hemostatics , in various combinations . Also, in this group there were included cases that received rFVIIa therapy but where selection criteria, imaging or treatment protocol was not fully respected
- ⇒ **Group C** 40 cases selected based on pre-established criteria, treated with a single dose of 20 µg / kg of rFVIIa within 4 hours from the

symptoms onset followed by treatment with vitamin K 40 mg / day divided in 4 doses, for 5 days

CLINICAL STUDY

The second chapter of the special part included the analysis of the epidemiological and clinical parameters; data were obtained both from clinical observation sheets and rFVIIa cases report forms .

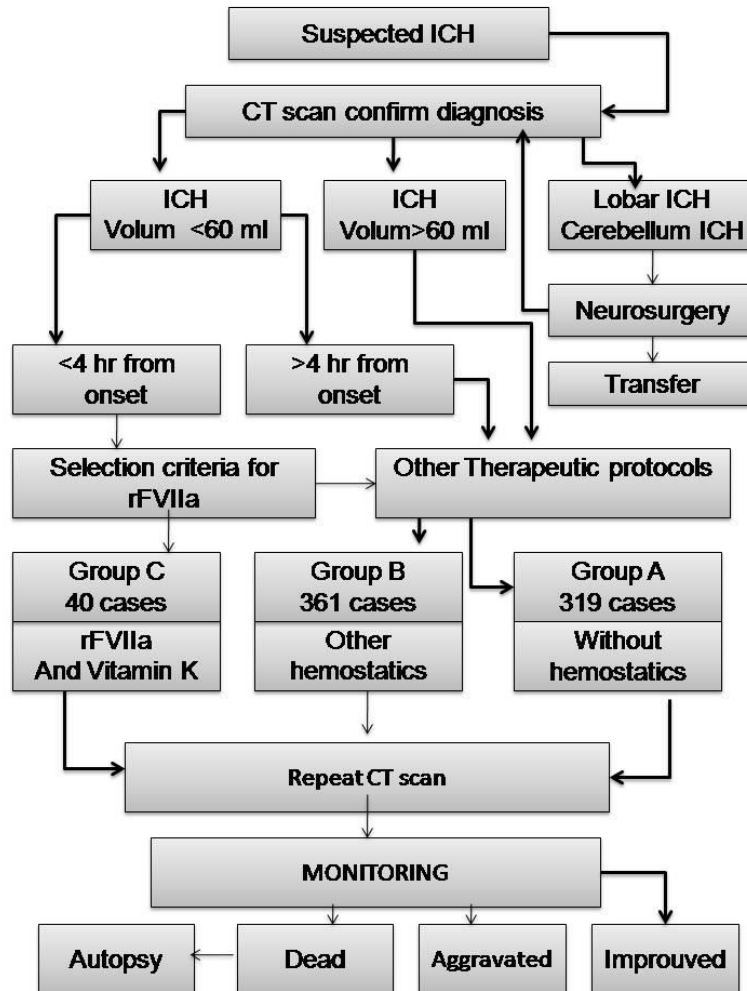


Figure 1: Algorithm for diagnosis and treatment of patients

MORPHOLOGICAL STUDY

The third chapter focused on morphological analysis; information was obtained from :

- Computed Tomography images
- Autopsy - examining different parts of the brain during autopsy in order to determine the diameters of the hematoma and collect tissue samples for the microscopic examination.

Hematoma volume was determined by the ABC / 2 method. Although this technique can result in errors, it was preferred do to the short time in which hematoma volume was obtained (Kothari et al. , 1996 Divani et al, 2011)

The samples were subjected to conventional histological processing techniques. Stains that we used were both classic and common for the different components of the vascular structures : hematoxylin - eosin (HE) for morphological evaluation and van Gieson , Goldner , CD34 immunostaining for qualitative assessment of the vascular structures .

Histopathological findings were selected using an Olympus microscope .

THE CLINICO-MORPHOLOGICAL CORRELATIONS

The last chapter of the special part aimed to establish correlations between different parameters of morphological and clinical evaluation of cerebral hemorrhage.

Statistical analysis

For some of the clinical or morphological parameters scale of stratification were used. Categorical data were analyzed using chi-square test and linear regression. Some data with normal distribution were presented as mean \pm SD and compared using t test with two tails. P value of less than 0.05 was considered significant.

RESULTS AND DISCUSSION

CLINICAL STUDY

The analysis of all clinical parameters in the three study groups yielded the following results :

- Increased incidence of ICH in cold season, with peaks of incidence in December and January
- Most patients were from countryside areas , with a slight predominance of ICH in male patients
- Cerebral hemorrhage occurs at relatively young age, immediately after the age of 45 with upward trend until age of 65.
- Severe hypertension was present in most of the patients. Dyslipidemia , alcohol and smoking were the most frequent risk factors associated with ICH, after hypertension
- Stroke severity was moderate to severe in most cases, often associated with impairment of consciousness
- The best neurological improvement has been achieved in patients of group C
- There were no thromboembolic events in the group C. The highest number of thromboembolic events was observed in group A.
- A third of cases had poor outcome resulting in patients death or rapid discharged at the request of their family/carers. Group B is where there have been most unfavorable outcomes. The best outcome was recorded in patients of group C where there have been no deaths or worsening of general condition
- Average length of stay in hospital for the patients treated with recombinant activated Factor VII was 9.4 days. In the other study groups , the average length of stay in hospital was shorter due to the deaths or the rapid discharges on request after a short time of hospitalization.

MORPHOLOGICAL STUDY

Analysis of the macroscopic morphological characteristics of the various forms of cerebral hemorrhage has helped us to draw several conclusions:

- The most common location of intracerebral hemorrhage was in the deep gray matter . At this level, capsulo - thalamic area was the most common affected with a hematoma volume below 30 ml in all study groups
 - Lobar hemorrhages were located predominantly in the parietal area with a hematoma volume below 30 ml . Massive lobar hemorrhages with volume of over 60 ml affected the whole hemisphere in which they were located, with poor outcome regardless of the therapy that we applied
 - Brainstem haemorrhages were mainly very small pontine haemorrhages with less than 3 ml volume , while most of the cerebellum bleedings were small and did not require neurosurgical evacuation
 - A significant number of cases had intraventricular haemorrhage from the admission. Subarachnoid extension was one of the complication that we identified to a number of multilobar haemorrhages that died.
 - Vary degrees of perilesional edema was present on the CT images in more than one third of the cases
 - Some small and medium-hemorrhages complicated themselves by hematoma expansion causing the patient's death
 - Rapid and significant reduction of the bleeding was achieved only for the patients in group C
- Regarding the microscopic aspects, some clarifications have to be made:
- Vast majority of the cases had hypertensive disease either as a major risk factor or as a determining factor
 - .Degenerative changes of arterial and arteriolar wall did not suggest the presence of abnormal deposits of focal, amorphous material. Therefore we did not direct histopathological diagnosis toward to amyloid angiopathy and there was no required to perform special stains for amyloid (Congo red)
 - We haven't found fibrinoid necrosis outbreaks in full healthy vascular wall . Vascular lesions that we encountered and analyzed were interpreted as being the result of the harmful effect of chronic hypertension on intraparenchymal vascular structures
 - The lesions that we described were encountered both in vascular structures in the proximity of the hemorrhage, in the same hemisphere, as well as in its counterpart

CLINICAL - MORPHOLOGICAL CORRELATIONS

The purpose of hemostatic therapy is to arrest ongoing bleeding and minimize hematoma expansion, which is a major predictor of ICH death and disability (Dowlatshahi et al., 2013).

The success of any therapy requires first of all to save the patient's life.

The question is what caused the unfavorable outcome of some patients?

What are the factors that directly or indirectly influenced the outcome ?

The fourth chapter records the possible correlations between the different morphological and clinical parameters of cerebral hemorrhage .

The analysis revealed the following:

- The outcome of the patient with cerebral haemorrhage was directly influenced by the severity of neurological impairment at admission expressed by GSC and NIHSS scores.
- Thromboembolic events that occurred during the hospitalization weren't treatment-related but they influenced the outcome and caused the death of the patients

- There was an inverse relationship between length of hospitalisation and the severity of bleeding and a directly relationship between length of hospitalisation and the patient positive outcome, especially for the deep gray matter location of haemorrhage.
- Cerebral haemorrhages larger than 60ml, arising from the deep gray matter had poor outcome
- Poor outcome is associated with extension into the subarachnoid and intraventricular spaces.
- Severity of the neurological impairment assessed by GCS and NIHSS scores was dependent of hematoma volume, topography and the presence of intraventricular haemorrhage
- Lobar hemorrhages were associated with severe impairment of consciousness , while severity of the neurological deficit was related to the deep gray matter ICH
- Massive, deep originated hemorrhages are directly influenced by the severity of hypertension and frequently complicate themselves with intraventricular extension

CONCLUSIONS

Finally, we summarized all clinical and morphological parameters from the three study groups and we tried to draw the profiles that had emerged from their bundling which in our opinion are as follows :

The most commonly encountered ***clinical profile*** of the patient with intracerebral hemorrhage was: male, average age 65, from countryside, known history of neglected severe hypertension, dyslipidemia, almost always smoker and alcohol drinker, bleeding occurred most frequently in the winter and was associated with moderate to severe neurological impairment.

The most commonly encountered ***morphological profile*** of the hematoma was: hematoma with volume less than 30 ml located in the capsulo-thalamic or parietal area, in the left hemisphere, with perilesional edema present on admission, with expansiv potential, sometimes complicated by intraventricular haemorrhage, that can occur on a background of preexisting artherosclerotic lesions. The range of variation of this profile can stretch from very small hemorrhages under 3 ml volume, such as the pontine ones, to the massive lobar hemorrhages with volume of over 60 ml, complicated by intraventricular and/or subarachnoid space extension.

The two fundamental aspects of the ***dynamic evolutiv profile*** of hematoma were:

- unfavorable clinical outcome resulted in the death of patients of the massive bleeding with volume of over 60 ml., regardless of the treatment protocol that we applied
- hematoma expansion for small and medium bleedings, regardless of location and unprotected by rFVIIa and Vitamin K therapy.

Profile of an effective therapy addressed to hemorrhagic stroke can take three aspects:

- therapeutic protocol free of hemostatics
- therapeutic protocol with conventional hemostatics
- therapeutic protocol with rFVIIa and Vitamin K

Analyzing all, our study showed that the last one may be the only effective therapy which has been proven to significantly reduce hematoma expansion.

Profile of a potential candidate for rFVIIa and Vitamin K therapy may be as follows: patients age under 65 years, who meets temporal and clinical criteria, with severe hypertension on admission, with a moderate to severe neurological impairment caused by a spontaneous intracerebral hemorrhage located deep in the gray matter, with an average volume of 30 ml.

SELECTIVE REFERENCES

- Chou, C.J., Inks, E.S. & Josey, B.J. 2013, "Vitamin K: a structural basis for the design of novel neuroprotective agents?", *Future medicinal chemistry*, vol. 5, no. 8, pp. 857-860.
- Demchuk, A.M., Dowlatshahi, D., Rodriguez-Luna, D., Molina, C.A., Blas, Y.S., Dzialowski, I., Kobayashi, A., Boulanger, J., Lum, C. & Gubitz, G. 2012, "Prediction of haematoma growth and outcome in patients with intracerebral haemorrhage using the CT-angiography spot sign (PREDICT): a prospective observational study", *The Lancet Neurology*, vol. 11, no. 4, pp. 307-314.
- Divani, A.A., Majidi, S., Luo, X., Souslian, F.G., Zhang, J., Abosch, A. & Tummala, R.P. 2011, "The ABCs of accurate volumetric measurement of cerebral hematoma", *Stroke*, vol. 42, no. 6, pp. 1569-1574.
- Dowlatshahi, D., Hogan, M.J., Sharma, M., Stotts, G., Blacquiére, D. & Chakraborty, S. 2013, "Ongoing bleeding in acute intracerebral haemorrhage", *The Lancet*, vol. 381, no. 9861, pp. 152.
- Earnshaw, S.R., Joshi, A.V., Wilson, M.R. & Rosand, J. 2006, "Cost-effectiveness of recombinant activated factor VII in the treatment of intracerebral hemorrhage", *Stroke*, vol. 37, no. 11, pp. 2751-2758
- Gely - Pernot, A., Coronas, V., Harnois, T., Prestoz, L., Mandairon, N., Didier, A., Berjeaud, J.M., Monvoisin, A., Bourmeyster, N. & De Frutos, P.G. 2012, "An Endogenous Vitamin K - Dependent Mechanism Regulates Cell Proliferation in the Brain Subventricular Stem Cell Niche", *Stem Cells*, vol. 30, no. 4, pp. 719-731.
- Kothari, R.U., Brott, T., Broderick, J.P., Barsan, W.G., Sauerbeck, L.R., Zuccarello, M. & Khoury, J. 1996, "The ABCs of measuring intracerebral hemorrhage volumes", *Stroke*, vol. 27, no. 8, pp. 1304-1305.
- Lloyd-Jones, D., Adams, R.J., Brown, T.M., Carnethon, M., Dai, S., De Simone, G., Ferguson, T.B., Ford, E., Furie, K. & Gillespie, C. 2010, "Heart disease and stroke statistics—2010 update A report from the American Heart Association", *Circulation*, vol. 121, no. 7, pp. e46-e215
- Mayer, S.A., Brun, N.C., Begtrup, K., Broderick, J., Davis, S., Diringer, M.N., Skolnick, B.E. & Steiner, T. 2005, "Recombinant activated factor VII for acute

intracerebral hemorrhage", *New England Journal of Medicine*, vol. 352, no. 8, pp. 777-785.

Mayer, S.A., Brun, N.C., Begtrup, K., Broderick, J., Davis, S., Diringer, M.N., Skolnick, B.E. & Steiner, T. 2008, "Efficacy and safety of recombinant activated factor VII for acute intracerebral hemorrhage", *New England Journal of Medicine*, vol. 358, no. 20, pp. 2127-2137.

PERSONAL REFERENCES

Articles published in MEDLINE and BDI journals

Stancu, C.C., Pleșea, I., Enache, S., Diaconescu, R., Cameniță, A. & Tenovici, M. 2011, "Morphoclinical study of intracerebral hemorrhage with subarachnoid effusion", *Rom J Morphol Embryol*, vol. 52, no. 1 Suppl, pp. 263-271.

Stancu, C. C., Diaconescu, R. 2012, „Recombinant Activated Factor VII for bilateral spontaneous basal ganglia haemorrhage with tetraventricular extension-case report”, *Analele Universitatii Dunarea de Jos din Galati*, No 2, pp. 21-23.

Abstracts published in national and international journals

Diaconescu, R., Stancu, C. C., Coteanu M.F. 2013, „ Hemostatic therapy for acute intracerebral hemorrhage”, *Romanian Journal of Neurology/ Revista Romana de Neurologie*, vol. XII, no. 1 Suppl, pp. 49-50.

Diaconescu, R., Stancu, C. C., Coteanu M.F. 2013, „ A comparative effectiveness study of recombinant activated factor VII in off-label use: monotherapy versus combination therapy for acute intracerebral haemorrhage”, *Journal of the Neurological Sciences*, vol. 333, Supplement 1, pp. e279.

Communication in national and international scientific meetings

Diaconescu, R., Stancu, C. C., Coteanu M.F. 25 septembrie 2013, „A comparative effectiveness study of recombinant activated factor VII in off-label use: monotherapy versus combination therapy for acute intracerebral haemorrhage”. The XXI World Congress of Neurology, Viena, Austria.

Diaconescu, R., Stancu, C. C., Coteanu M.F. 15-18 mai 2013, „Hemostatic therapy for acute intracerebral hemorrhage”. Al XI-lea Congres al Societății de Neurologie din România, București

Diaconescu, R., Stancu, C. C., Coteanu M.F. 7-8 iunie 2013, „Studiul clinic al hemoragiei intracerebrală spontană la Spitalul Județean de Urgență Slatina în perioada 2008-2012”, Zilele UMF, Craiova