

**UNIVERSITY OF MEDICINE AND PHARMACY OF CRAIOVA
DOCTORAL SCHOOL**

**CONTRIBUTIONS TO THE STUDY OF AVASCULAR NECROSIS
OF THE FEMORAL HEAD IN ADULTS
(DOCTORAL THESIS SUMMARY)**

**Scientific coordinator
Prof. Dr. GEORGESCU ION, MD, PhD**

**PhD student
Dr. ZUGRAVU ANA GEORGIANA, MD**

CRAIOVA 2013

Content

Part I. General

Chapter 1 Introduction. Definition. Terminology	4
Chapter 2 Etiology	4
Chapter 3 Pathogenesis	5
Chapter 4 Pathology	6
Chapter 5 Clinical manifestations.....	6
Chapter 6 Staging	7
Chapter 7 Treatment	7

Part II. Personal Contribution

Chapter 8-11 Virtual study	8
Chapter 12 The analysis of surgical therapeutic procedures	12
Chapter 13 Study of 160 hips classified according to the Ficat-Arlet criteria.....	12
Chapter 14 Analysis of the 132 hips classified according to the Steinberg criteria.....	15
Chapter 15 Bipolar uncemented prostheses	16
Chapter 16 Total arthroplasty	17
Chapter 17 Conclusion	19
Selective references.....	20

Key words: avascular necrosis femoral head, MRI, arthroplasty, biomechanics.

Chapter 1. Introduction. Definition. Terminology.

Avascular necrosis of the femoral head (AVNFH) is a severe orthopaedic disorder because of the evolution towards joint damage, in the absence of an early diagnosis and proper treatment. Even if over the last 20 years the interest in this disorder has increased significantly, it continues to be a challenge for the orthopaedist and for other specialists receiving patients with hip pain: family physician, balneologist, rheumatologist, internist.

Initially, the term *aseptic necrosis* was used in order to distinguish this pathological process from infectious bone necrosis.

The terms *avascular necrosis*, *ischemic necrosis*, *bone infarction* (used in different schools) suggest a unique (vascular) aetiology and a unique pathogenic mechanism. *Avascular* or *ischemic necrosis* refers to the cases of epiphyseal / subarticular damage and the term *bone infarction* refers to the cases with metaphyseal or diaphyseal damage.

Given that multiple factors are involved in the development of necrosis and that the pathogenesis is not yet clarified, ARCO (Association Research Circulation Osseous) established in 2001 the following elements of definition and terminology:

*Bone necrosis is a disorder causing bone death, the term suggested for its designation being **osteonecrosis**.*

The idiopathic osteonecrosis of the femoral head is a disorder causing the ischemic osteonecrosis of the femoral head in the absence of the infection or trauma and leads to the damage of the femoral head and to secondary arthrosis. Even if cortisone drugs and alcohol are etiologic factors well known, osteonecrosis induced by corticotherapy and alcohol consumption was included in idiopathic osteonecrosis, because the pathogenic mechanisms are not defined.

The following disorders are excluded from the category of idiopathic osteonecrosis: Perthes' disease, osteonecrosis secondary to femoral neck fractures, hip dislocations, radiation necrosis and Caisson's disease necrosis.

Osteonecrosis usually develops in the young adult (30-50 years), active from a social and professional point of view, for which reason it has a significant impact over his/her life. An early diagnosis is absolutely necessary, being the premise of an efficient treatment meant to delay arthroplasty and improve the patient's life quality.

Study objectives: early identify the risk factors, prevent the degradation of articular components- particularly the femoral head and improve life quality. The **purpose** is to define the proper therapeutic protocol. To this end, it is necessary to systematise the information in the literature relating to the etiology, pathogenesis, and pathological anatomy and to assess the importance of the therapeutic procedures used.

Chapter 2. Etiology

The causes of aseptic necrosis are multiple. A first classification makes the distinction between traumatic causes (determined by fractures, dislocations), identified and unidentified atraumatic causes (idiopathic AVNFB).

Identified atraumatic causes are:

1. Connective tissue diseases: systemic lupus erythematosus (SLE), rheumatoid arthritis (RA), vasculitis, antiphospholipid syndrome.
2. Haematological diseases: sickle cell anaemia, thalassemia, coagulation disorders.
3. Infiltrative diseases: Gaucher's disease, solid tumours.
4. Metabolic diseases: hyperuricaemia. Gout, hypercalcaemia, osteomalacia, dyslipidemia.
5. Diseases associated to fat necrosis of the bone marrow: pancreatitis, pancreatic carcinoma.
6. Gastrointestinal diseases: inflammatory bowel diseases.
7. Caisson's disease.
8. Endocrine diseases: hyperparathyroidism, Cushing disease.
9. Renal diseases: chronic renal failure, renal transplantation.
10. Corticotherapy.
11. Cytotoxic agents: vinblastin, vincristine, cisplatin (intra-arterial), cyclophosphamide, methotrexate, bleomycin, 5-fluorouracil.
12. Alcohol.
13. Radiation.
14. Pregnancy.

Chapter 3. AVNFH Pathogenesis

Necrosis process is a consequence of the ischemia occurring after blood flow alteration. Blood flow alteration may be: total or partial and it occurs suddenly (acute) or slowly (chronic). Blood flow can be altered in the extra-articular or intra-articular area. In the extra-articular area the problems might develop on the common femoral artery, on the deep femoral artery or on the circumflex arteries.

In the intra-articular area the vessels feeding the femoral head may be disrupted following femoral neck fractures, comminuted pertrochanteric fractures or they may be compressed by haematoma or hydrarthrosis.

3.1. Femoral Head Vascularisation. Development Stages

In order to understand the modifications of the blood flow it is necessary to be acquainted with the vascularisation of the femoral head and upper extremity of the femur. The vascularisation of the femoral head and of the upper extremity of the femur depends on the age. Thus, Trueta describes six stages of development of the blood flow in the upper extremity of the femur and femoral head:

1. The foetal type (the first four months of life), is represented by the upper arterial group (4-6 branches), the lower arterial group and the round ligament vessels, with a terminal arrangement.
2. The infantile type (fourth month – 3 years) is represented by a thick arterial network. In this period the ossification nucleus of the femoral head appears and the growth plate separating the femoral head blood flow from the metaphyseal blood flow is formed. The vessels are distributed as follows: upper group (lateral epiphyseal) properly developed with a major contribution, the lower group with a small contribution and the vessels of the round ligament that do not have any contribution.
3. The intermediary type (3-8 years) is represented by lateral epiphyseal vessels, which are the most important in terms of nutritional intake, and the metaphyseal intake is very low. It is the critical vascular period when the osteochondritis might develop.
4. The pre-teenager type (8-10 years) distinguishes by the significant role of the round ligament artery, occurrence of anastomoses between the lateral epiphyseal artery and the medial epiphyseal and also by the development of the first anastomosis between the vessels feeding the femoral head.
5. The teenager type is represented by the lateral epiphyseal artery feeding the largest part of the femoral head, the occurrence of interconnected vessels in the epiphyseal plates and by a low flow in the round ligament artery.
6. The adult type is represented by A. anterior circumflex artery, B. posterior circumflex artery, A2 common femoral artery, A3 deep femoral artery

Chapter 4. Pathological Anatomy in AVNFH

Medullar and trabecular lesions are described. Medullar lesions consist of: necrosis of fat bone marrow, highlighted by lipocyte fragmentation, occurrence of the foam cells and empty cavities and necrosis of haematogenous marrow in the form of granular necrosis followed by the creation of a replacing fibrous tissue. Trabecular lesions consist of partial lesions of trabeculae followed by total trabecular necrosis leading to micro-fractures and creation of osteoid tissue.

Chapter 5. Clinical Manifestations

The clinical presentation in AVNFH is poor. The patient, aged 20-50 years, presents for hip or knee pain, the pain being insidious, deep, progressive, increasing with effort. The clinical examination reveals the limitation of the internal rotation and positive Faber test in the early stages and we notice the limitation of movements in all regions, limping, positive Trendelenburg, shortening and vicious positions in the advanced stages.

The history might indicate risk factors.

Following the clinical exam the suspicion of AVNFH is raised. The positive diagnosis is given based on the diagnosis criteria obtained by anamnesis, clinical exam, radiological exam, MRI, scintigraphy, drill biopsy.

Major criteria:

1. *MRI* = band in hyposignal T1
2. Scintigraphy = appearance of “cold in hot”
3. Histology = medullar and trabecular necrosis
4. Radiology =
 - a) femoral head depression
 - b) demarcation sclerosis in the femoral head
 - c) half-moon sign – subchondral fracture line

Defined AVNFH = 2 or more MAJOR CRITERIA.

Minor criteria:

1. Symptoms: pain upon orthostatism and walking
2. History: risk factors - corticotherapy
- ethanol
3. Scintigraphy: “cold or hot” appearance
4. MRI: hyposignal in T1, without band arrangement
5. Radiology:
 - a) femoral head depression
 - b) radio-transparent cysts or granular sclerosis
 - c) flattening of the upper region of the femoral head
 - d) normal joint space

Probable AVNFH – a major criterion and four minor criteria, one mandatory from a radiological point of view.

Chapter 6. AVNFH Staging

Modified Steinberg Staging:

Stage 0 - Normal radiographs, MRI and bone scan

Stage I – Normal radiographs; abnormal MRI or bone scan

Stage II – Abnormal lucency or sclerotic site in femoral head

Stage III – Subchondral collapse (ie, crescent sign) without flattening of femoral head

Stage IV – Flattening of the femoral head; normal joint space

Stage V – Joint space narrowing, acetabular changes, or both

Stage VI – Advanced degenerative changes

- Stages I-V are further subdivided according to the percentage of femoral head involvement: A (< 15%), B (15-30%), or C (>30%).

AVNFH Classification

I Radiology Classification – Japanese Committee

- Type I – demarcation sclerosis - IA, IB, IC
- Type II – femoral head flattening
- Type III – transparent cysts
 - A – outside the load-bearing area
 - B – in the load-bearing area

II ARCO Classification

- Type A - <1/3 of the supporting area
- Type B - <2/3 of the supporting area
 - C1 – laterally extended without reaching the acetabular edge
 - C2 – comes into contact with the acetabular edge

Chapter 7. AVNFH Treatment

The intention of the treatment is to stop the evolution of lesions, prevent femoral head collapse, avoid arthrosis.

The treatment protocol depends on: lesion stage, necrosis location and extension, related risk factors, age

The therapeutic means are: 1. non-surgical and 2. surgical

I The treatment by non-surgical means is not efficient; in 92% of patients the lesions progress in the following 12-24 months.

Electric stimulation and oxygen therapy are currently studied.

II Surgical means:

1. aid procedures: a) decompression by drill biopsy, b) bone graft, c) osteotomies, d) combined methods;
2. reconstructive procedures: a) bipolar arthroplasty, b) total arthroplasty.

II. The special part includes:

1. Virtual study of the hip joint behaviour while walking. The virtual study was conducted at the Faculty of Mechanical Engineering, University of Craiova, by Prof. Popa Dragoş Laurenţiu.

2. Analysis of the results of surgical therapeutic procedures.

Chapters 8-11 contain a virtual study the behavior of virtual hip joint during walking

From the study of the hip joint behavior during driving, climbing stairs, standing-monopodal and bipodal-, sitting in this paper we used only kinematic parameters to analyze. For this we used a three-dimensional model of pelvis-femur biomechanical chain components tibia-fibula, and foot. The model of the components hip, knee and ankle was performed using SolidWorks software that allows for three-dimensional parametric models. These parameterized three-dimensional models can be modified, edited, and also can be transferred to kinematic simulation programs or finite element analysis.

Finite element simulation results can be:

- Tension (stress)- on maps obtained by von Mises algorithm that provides information on finite elements -expressed in Pascals ($1\text{Pa} = 1\text{N/m}^2$);
- State of displacement (displacement)- on maps which provide information on the finite element nodes changing positions and expressed in millimeters (mm);
- The state of deformation (strain) - on deformation maps, a mechanical system that plays finite element elongation per unit length and expressed in millimeter / millimeter (mm / mm - dimensionless).

The following were explained by finite element analysis results for the femur and pelvis normal, but for different degrees of necrosis of the femoral head.

These bone components models were loaded in the module assembly where they were created the connections and plugs (joints) of the mechanical parts (hip, knee, connecting force, weight force replacing human contact with the ground forces, other parameters original kinematics). This biomechanical system was exported in a kinematic analysis and finite element.

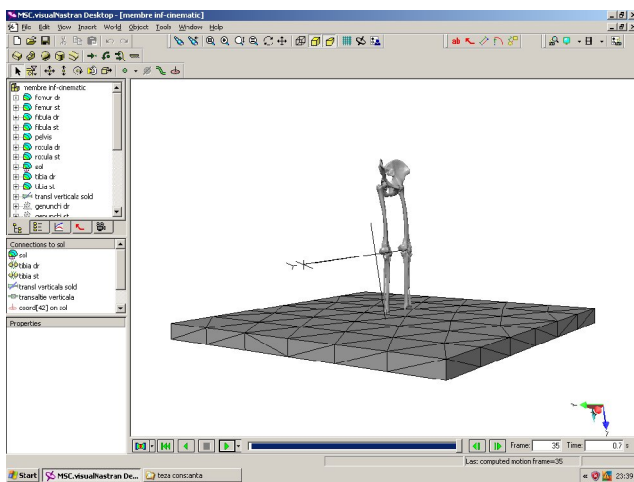
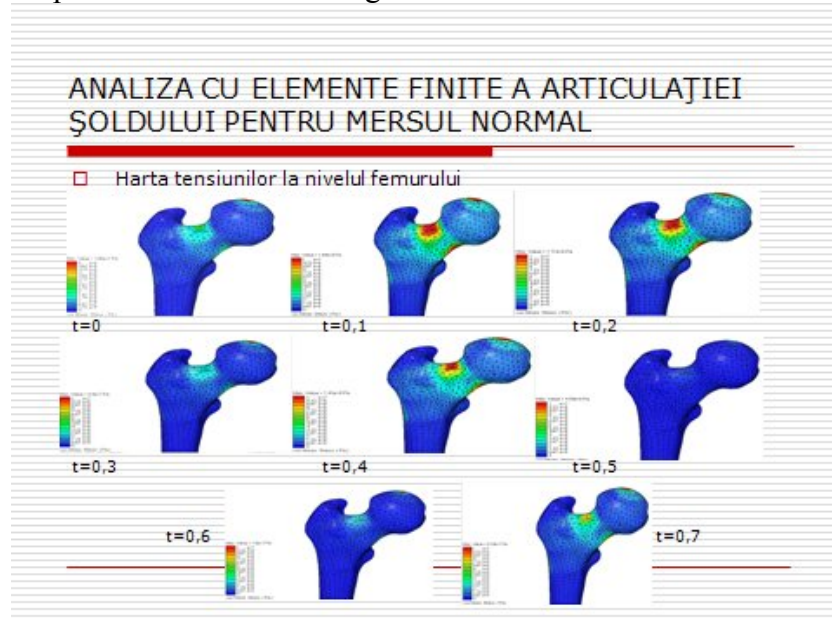


Fig.20. Bio-mechanical model for simulating human walking.

This model that includes key links, external forces and moments was simulated in terms of a kinematic analysis system. This simulation was performed for both normal hip- in summary I present just one example: the tensions in the femur -and the hip with osteonecrosis in the early stage and advanced respectively.

Map femoral stress-normal gait:



Analyzing diagrams mechanical parameters (voltage, displacement and strain) of the right femur and the pelvis were traced comparative charts below:

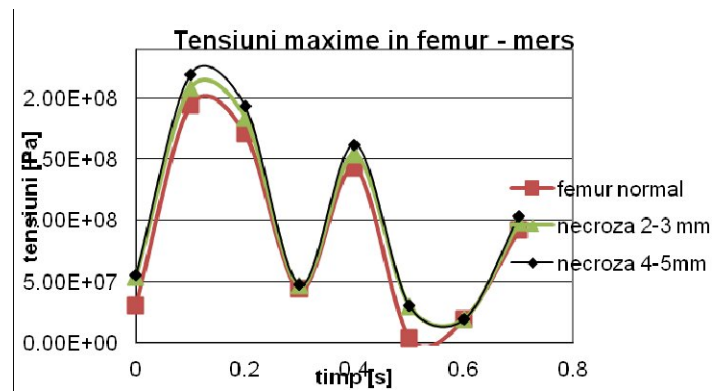


Fig.186. Maximum tensions in femur for the studied situations.

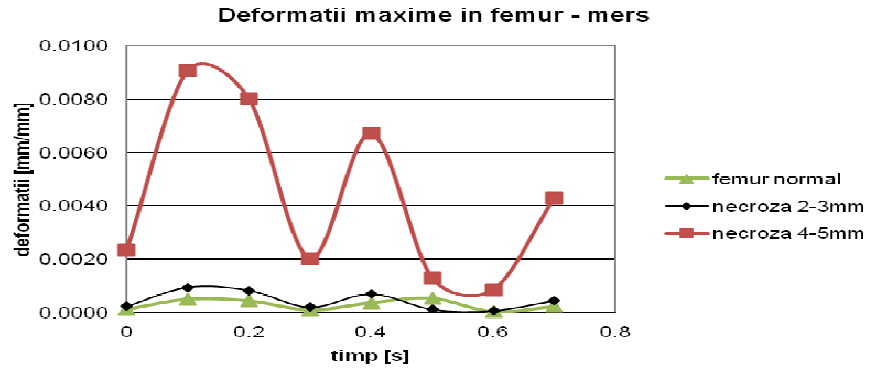


Fig.187. Maximum femur deformations for the studied situations.

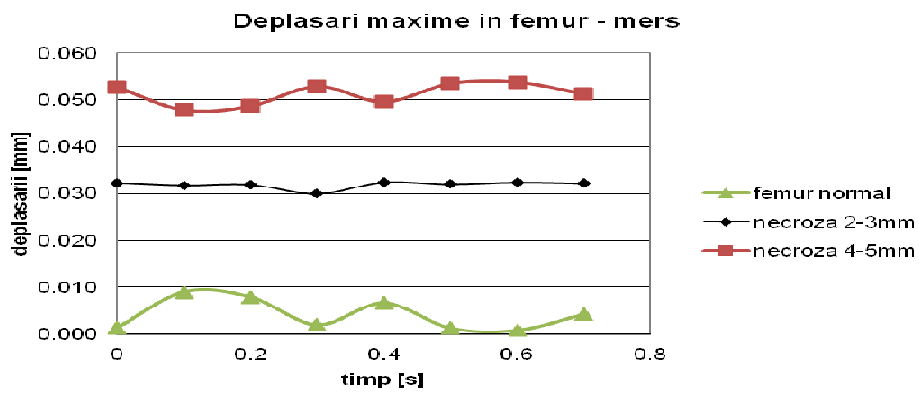


Fig.188. Maximum displacements in the femur for the studied cases

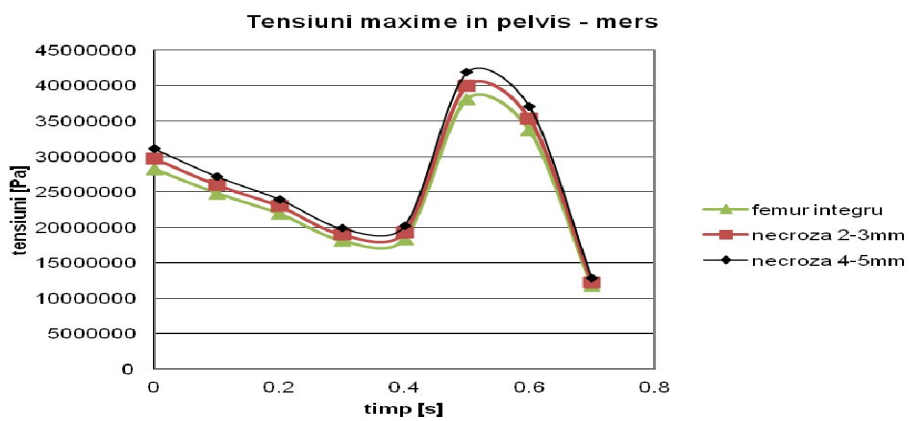


Fig.189. Maximum tensions in pelvis for the studied situations

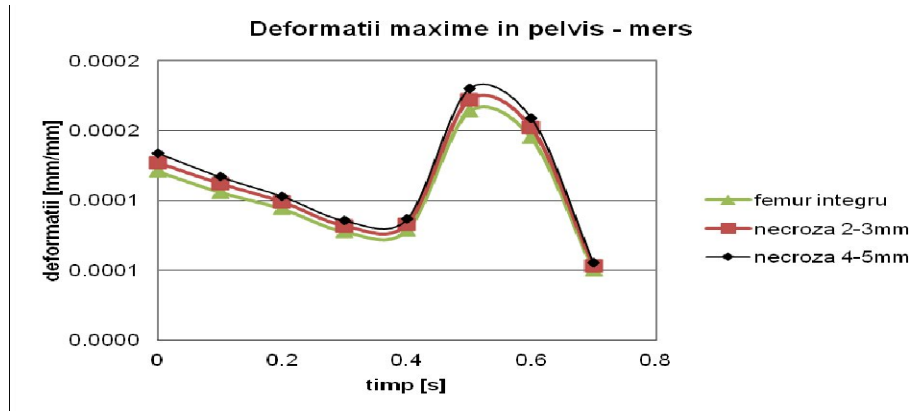


Fig.190. Maximum pelvis deformations for the studied situations

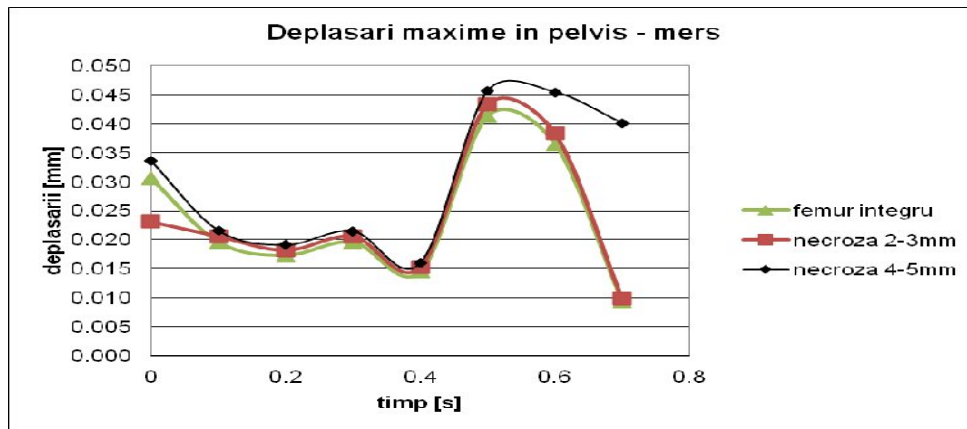


Fig.191. Maximum displacements in the pelvis for the studied cases.

In this virtual study we showed the place of stress concentration, displacements and deformations of the femoral head necrosis favoring the formation of cysts in the femoral head and neck and clogging of the femoral head. The acetabular lesions appear only late due to joint incongruity arising from loss of femoral head sphericity .

The femoral head with necrosis shows slight increased tensions compared to the normal head. But large differences occur in the deformation and displacement, which explains:

- evolution of patient pain and impaired walking as destructive process already initiated by hypoperfusion and edema is rapidly increased.
- Changes that occur in the femoral neck with the formation of cysts, although it is not subject necrotic process itself;
- Clinical improvement that occurs immediately after drilling decompression, because drilling reduces tensions in the affected area and thus reduces pain.

Also, perhaps the most important contribution of this virtual model could come by personalizing; together with MRI it could help a more accurate necrosis staging and choosing the treatment method with highest success rate for a particular case. In other words we allow customization of prognosis and surgical method, which will improve the patient's evolution.

Chapter 12. Analysis of the Results of Surgical Therapeutic Procedures

Results of AVNFH treatment in adults

298 hips suffering from non-traumatic AVNFH were analysed. The positive diagnosis and the classification were made

- a) before using MRI according to Ficat-Arlet criteria – 160 hips
- b) after using MRI based on Steinberg criteria - 128 hips

Chapter 13. Study of the 160 hips classified according to Ficat Arlet criteria

(before the advent of MRI)

Necrosis stages identified:

- stage 0 – 12 hips (dumb hip)
- stage 1 – 16 hips
- stage 2 – 2A 20 hips
 2B 24 hips
- stage 3 – 45 hips
- stage 4 – 43 hips

For the 160 hips of this series the following surgical operations were carried out:

- 58 decompression biopsy drills
- 45 osteotomies
- 22 non-cemented bipolar prostheses (NBP)
- 49 non-cemented total prostheses (NTP)
- 10 cemented total prostheses (CTP)

1. clinical– subjective- criteria - using HARRIS parameters
2. objective criteria – radiology appearance

■ HARRIS score used synthetically assigns the following ratings:

- for pain – 50 points
- for functionality (activities) 25 points
- mobility 25 points
- normal 100 points

The results are assessed as follows:

- excellent 85-100 points
- good 75-85 points
- satisfactory 65-75 points
- failure under 65 points

Decompression and biopsy drill has the following effects: enables revascularization of necrotic areas, clears the peri-adipocyte sinusoids by tissue decompression restoring microcirculation and thus decreases spongius bone pressure, clears the cortical vascular foramen reducing coronary spasm existing in this region, therefore it has decompression action with vascular and canalicular relaxation interrupting the initial vicious circle of intramedullary hypertension. The antalgic effect is sometimes spectacular: the pain disappears immediately in the most part of patients,

Decompression drill is efficient in stage I in 75% of cases and only in 55% in stage II.

Decompression drill associated to biopsy is indicated in stage 0 and I both for establishing the diagnosis and for the favourable therapeutic effect in over 70% of cases.

The cases with metabolic disorders shall be corrected in pre- and post-drill. In the cases with cortisone treatment, decompression drill is not efficient and it shall be avoided; it may even accelerate the evolution towards sequestrum collapse.

The analysis of the unfavourable results obtained in the hips in stage I and stage II indicates that in the cases in which the cause is not controlled the evolution towards worsening is constant. In this category there are the cases with cortisone treatment in progress for different disorders in which this medication may not be interrupted (rheumatoid arthritis, lupus erythematosus etc.) and metabolic disorders (obesity, alcoholism) that can not be controlled.

In conclusion the best results of decompression drill are obtained in stages 0 and I. Irrespective of the evolution stage the metabolic disorders shall be controlled. The patients undergoing cortisone treatment shall not be subjected to decompression drill.

13.2. Osteotomies in AVNFH

45 osteotomies were performed (inter-trochanteric): 18 in stage II, 25 in stage III and 2 in stage IV according to Ficat-Arlet classification.

The principle of osteotomies is to bring an undamaged area of the femoral head inside the cotyloid cavity in a supporting position- in the maximum pressure area. The maximum pressure area is assimilated to 30° on both sides of the apex and equals 60°. Effects of osteotomies:

- decrease in intramedullary pressure;
- avoid stress on the necrosis area during its healing;

Purpose:

- healing of the necrosis area;
- stop or delay degenerative lesions.

Indication criteria:

- necrosis location;
- necrosis extension;
- mobility within flexion limits > 90°, ER-IR= 20°, Abd- Add= 30°;
- age- preferably in patients under 45 years;
- unilateralism;
- known cause the control of which was possible.

The operative planning is made according to:

I Radiology results

II Coxometry

I Radiology results use:

- Anterior-posterior pelvis radiography and Lequesne's false profile
- Front and profile centring tests
- Tomography in the same incidents
- Sagittal reconstruction

There were performed:

- varization osteotomy - 6- in stage II
- flexion osteotomies - 12- in stage II
- 25 – stage III.

Varization osteotomy is indicated if the lesion may be inserted inside the lateral border of the cotyloid cavity, therefore the side part of the head is undamaged.

Valgisation osteotomy is used if the procedure mentioned above fails and the undamaged medial part of the head is brought in the supporting area.

Combined flexion or extension osteotomies are used in order to bring the healthy head area in supporting position.

Trans-trochanteric rotation osteotomies are intended to bring the healthy area in the supporting position by head-cervix rotation.

1. Osteotomies are efficient provided that they are applied in cases in stage 2-3 Ficat correctly selected.
2. In the first 2 years after osteotomy the pain, mobility and functionality are improved in over 70% of patients. Furthermore, it was noticed that necrosis lesions in the femoral head change their shape and that the height of the joint space is maintained.
3. The clinical and radiological deterioration begins 4-5 years after osteotomy so that within the period comprised between the 7th and 10th year 40% of patients required the implantation of non-cemented total prosthesis.

13.3 Non-cemented Bipolar Prostheses

Twenty-two non-cemented bipolar prostheses were implanted in 22 patients suffering from AVNFB stage 3 (Ficat-Arlet); joint space with unmodified height, cotyloid cavity with black cartilage upon the intra-operative macroscopic exam.

The results were assessed at 6 months, 1 year, 5 and 10 years after implantation using Harris criteria and the radiology image.

Five years after the implantation of NBP the results are preserved with a score above 65 points in all patients; there should be mentioned that 4 patients (18%) complain of discomfort or minor pain upon walking on big distances, that are no longer present after rest or intermittent NSAIDs therapy.

In the period comprised between the 5th and 8th year from the implantation of NBP 6 patients (27%) required total prosthesis by the implementation of non-cemented acetabular components because of cotyloid damage or nucleus fixation in a vicious position. There were as well other 4 patients who underwent total prosthesis, therefore after 10 years 10 patients (45%) needed total prosthesis.

NBP implantation is a good solution offering all patients a quasinormal activity over a period of 7 years, delaying the use of total prosthesis by this time period.

The major indication of NBP is AVNFB in patients aged below 45 years. The results start to worsen after 7-8 years so that in 45% of patients (10 patients) it was necessary to totalize the cotyloid cup, and 55% (12 patients) are still satisfied with NBP.

Chapter 14. Analysis of the 132 Hips Diagnosed, Classified and Treated Using Steinberg Classification

The use of MRI enabled early diagnosis, accurate assessment of the extension of the lesion and of the progress, criteria based on which the surgical approach was decided.

The 132 hips were staged as follows:

- “dumb” hip– stage 0 contralateral to a AVNFH stage 2-3 = 7 hips
- stage I – 14 hips
- stage II – 20 hips
- stage III – 21 hips
- stage IV – 25 hips
- stage V – 24 hips
- stage VI – 21 hips

The following surgical operations were carried out:

- drills - 25
- flexion osteotomies – 27
- bipolar prostheses – 32
- non-cemented total prostheses – 44
- cemented total prostheses – 4

14.1 Results of the decompression drill, after 10 years, are as follows:

- the hips operated in stage 0, in 5 patients, did not have any clinical or radiological evolution, maintained a normal global Harris score (100 points). NB The biopsy performed at the time of the drill indicated necrotic lesions (death of fat cells, absence of osteocytes on the bone plates);
- the hips operated in stage I, have a quasinormal Harris score (over 90 points) in 6 hips, and in 5 hips Harris score decreased under 65 points, and the radiological modifications appeared and progressed unfavourably 3-4 years after the drill which required the implantation of non-cemented bipolar prostheses. Favourable result in 54.5%, failure- 45.5%
- the hips operated in stage II, had a favourable evolution in 4 cases, having a global Harris score of over 80 points and in 5 cases the evolution was unfavourable.

14.2 Osteotomies in AVNFH. Results after 6 months

14.3 After 6 months Harris score shows a significant improvement in all patients totalizing a score above 65. Thus in the hips operated in stage I- 5 patients and stage II- 11 patients, Harris score reaches over 80 points, as compared to 40-60 points before the operation, making 16 patients fall in the good result category.

The hips operated- 11 patients- in stage III- totalize a Harris score of 70 points as compared to 30 points before the operation and falls in the satisfactory result category.

14.4 Assessment of the results of flexions osteotomies after 2 years

The assessment was made using the detailed Harris criteria. The 27 flexion osteotomies performed in patients with AVNFH in stages I, II, III lead to good results in 16 patients (global Harris score above 80 points) and in 11 patients to satisfactory results (70 points).

After the flexion osteotomy carried out in stages I, II Steinberg good results are obtained, in all 16 cases, 2 years after osteotomy, having a score above 80 points.

14.5 Assessment of Osteotomy Results after 10 years.

Ten years after the osteotomy good and satisfactory results are maintained only in 69.2% of cases, 31.2% being considered failures with a Harris score under 65 points.

There was not a strict correspondence between the radiological appearance and clinical manifestations in all cases.

The analysis of the evolution of Harris score shows that the score starts to decrease after 6-7 years and accentuates gradually, the pain being the main symptom.

Thus, up to the 10 year-term it was necessary to implant non-cemented total prostheses in 31% of the patients having undergone flexion osteotomy.

Chapter 15. Non-Cemented Bipolar Prostheses in NACF

Thirty-two non-cemented bipolar prostheses were implanted in AVNFH classified according to Steinberg criteria: 10 in stage III and 22 in stage IV.

The surgical method is chosen based on the same criteria as in the cases classified according to Ficat-Arlet criteria, supplemented by the classification according to MRI in A, B, C and calculation of Koo angle on MRI and CT images.

Please note that MRI and CT highlight more precisely the limits of the necrosis area and provide information regarding the presence of lesions in the acetabulum, capsule and synovium and femoral cervix.

To this end increased attention shall be paid to the presence of lesions in the acetabulum which provide, if highlighted, a contraindication to bipolar prosthesis and require the implantation of non-cemented total prosthesis from the beginning.

The bipolar prosthesis was applied in all hips classified in stage III C, in the cystic forms within stage III irrespective of the extension of the lesion and in all cases classified in stage IV.

Six months after NBP implantation (in all patients) the improvements of Harris score in all components was noticed, which makes all patients satisfied, leading to quasinormal life.

They can walk long distances of over 2 km without using any supporting instruments, they can put their shoes on without difficulty, they can freely walk up and they can seat on the chair and then continue to walk without difficulty and with no hip pain.

Furthermore, they can use public means of transport or they can drive their private car.

One year after NBP implantation Harris score is better than the one after 6 months, all patients followed a recovery programme, (and thus) mobility increased in all areas, the walking distance is longer and while walking no supporting means are needed. The hip discomfort is maintained only in 4 patients (12.4%) and occurs after effort.

Five years after NBP implantation all patients live a quasinormal life, can walk without any supporting means unlimited distances, 30 patients (93.8%), 2 patients (6.2%) walk up to 2 km without any supporting means.

All patients can use public means of transport or they can drive their private car.

The other activities: walking, putting the shoes on, sitting on the chair are carried out with any difficulty.

The radiology exam does not indicate any signs of cotyloid damage or modifications in the femoral stem position.

The non-cemented bipolar prosthesis ensures a quasinormal activity in all patients in the first 5 years: walking is possible over high distances without using any supporting instruments; they may use any public means of transport.

Ten years after NBP implantation, 76% of patients continue to have a quasinormal activity, 24% complain of moderate or minor pain and use a stick for walking 1.5-2 km and avoid using public means of transport.

The radiographic exam 10 years after the implantation of the non-cemented bipolar prosthesis highlight the disappearance of the space between the nucleus and cotyloid cavity in 8 patients (24.8%), patients complaining of moderate or minor pain, using the permanent stick for walking and avoiding using public means of transport because of the discomfort felt when walking up and sitting on the chair.

These patients are further monitored in order to identify the moment when they need total prosthesis, by implantation of non-cemented cup. NBP is a solution to be chosen for patients aged up to 55 who suffer from AVNFH in stage III-IV Steinberg and who do not have cotyloid lesions. They ensure a quasinormal activity for minim 10 years in over 75% of patients.

The totalizing by implantation of non-cemented cup is required when the clinical distress occurs and cotyloid lesions are identified at the radiographic exam. Clinical distress: pain, decrease in movement amplitude, limping and limited walking, need to use a stick on short distances require radiography exam in order to identify the signs of cotyloid damage. The disappearance of the space between the nucleus and cotyloid cavity are the signs of distress they shall be sanctioned. In these situations a total prosthesis is required by implantation of non-cemented cup.

Chapter 16. Total Prostheses in AVNFH

One hundred and seven total prostheses were implanted for AVNFH, as follows:

- 93 non-cemented total prostheses (NTP):
 - FICAT- 49 - 10 in stage III;
 - 39 in stage IV;
 - Steinberg- 44 - 3 in stage IV- collapse > 4mm;
 - 22 in stage V;
 - 19 in stage VI.

- 14 cemented total prostheses (CTP):
 - FICAT – 10 in stage IV;
 - Steinberg- 4 - 2 in stage V;
 - 2 in stage VI.

NTP were applied and in stage III Ficat when alterations of the acetabular cartilage were identified macroscopically: colour modification, irregularities upon palpation with empty index or when examined using the magnifying glass. Thus, in 10 hips classified in stage III Ficat these alterations were identified, requiring the avoidance of implantation of non-cemented bipolar prosthesis (NBP).

Furthermore, NTP were also implemented in stage IV Steinberg, because of the existence of lesions in the acetabular cartilage found out during surgery or when the head collapse is higher than 4 mm.

Non-cemented total prostheses were all with HAP, both on the acetabular components and on the femoral components, head of Ø 28 and cervix on cone 12-14, variable lengths ranging from -3 to +5 mm.

For the acetabular components the application with 2-3 screws was used, placed at the hours 11-14, with variable lengths of 25-40 mm.

One year after the implantation of the prosthesis all patients are satisfied, the shortening was corrected in 26 of the 34 having a shortening before the implantation of the prosthesis, the pain was significantly modified in all patients, only 25.8% of those with NTP complain of minor discomfort in the thigh but it does not influence the other activities such as walking, walking up, putting the shoes on, sitting on the chair or using public means of transport. Thus, all patients live a quasinormal life 1 year after the implantation of the prosthesis, be it CTP or NTP.

Five years after the implantation of the prosthesis, the results are similar to those identified upon the 1 year-term; all patients are satisfied and can comfortably carry out the regular activities; they can walk without pain, can use public means of transport, can sit on a regular or high chair, are independent in terms of daily needs and can carry out activities requiring physical efforts.

Analysing the comparative table over the 10-year period for each parameter in Harris score, the following conclusions may be drawn:

1. The pain is present in all patients before implantation of the non-cemented (93 prostheses) or cemented total prosthesis (14 prostheses), the intensity being severe in 54 patients (51%), moderate in 47 patients (44%) and minor in 5 patients (5%).

After the implantation of the prosthesis, upon the 6-month, 1-year, 5-year and 10-year examination:

- the pain disappeared in all patients with cemented total prosthesis (14 patients = 100%) and this situation is maintained up to the examination carried out after 10 years;

- the pain is absent in 54 patients (57.8%) with non-cemented total prosthesis, and the remaining 39 patients (42,2%) complain of discomfort in the thigh upon the 6-month and 1-year examination, whilst 5 years after the implantation of the prosthesis only 3 patients (3.3%) complain of minor pain in the hip or on the anterior side of the thigh. Furthermore, this percentage is maintained 10 years after the surgery.

Five years after the implantation of the prosthesis, the results are similar to those identified upon the 1 year-term; all patients are satisfied and can comfortably carry out the regular activities; they can walk without pain, can use public means of transport, can sit on a regular or high chair, are independent in terms of daily needs and can carry out activities requiring physical efforts.

2. Walking was improved in all patients as follows:

2.1. - if before the implantation of the prosthesis 59 patients suffered from severe limping and 37 patients suffered from moderate limping, caused by pain, shortening and muscular failure (particularly gluteal muscles), after the implantation of the prosthesis only 8 patients walk limpingly after 10 years and this is caused by shortening. By correcting the shortening, by addition, this limping may be improved.

2.2.- the walking distance without support was modified as follows:

- before the surgery it was necessary in all patients for distances of over 1.5 cm, using either a stick (45 patients) or a crutch (61 patients), the unlimited distance not being accessible for any patient;

- after the implantation of the prosthesis 83 patients can walk on an unlimited distance without any support, 24 patients using a stick when walking over distances above 2-3 km.

3. Movement amplitude increased in all areas, in all patients and is maintained over the entire period of 10 years after the implantation of the prosthesis.

The absence of the pain and increased mobility ensure that walking and the other activities are carried out without difficulty, the patients being able to live a quasinormal life.

4. The other activities: putting the shoes on, sitting on the chair improved significantly.

All patients can easily put their shoes on. They can walk up without any difficulty and in an easy way if they hold on to the banister and they can comfortably sit on the chair if they use a higher chair.

We recommend for all patients to use a long shoe horn, to walk up holding on to the banister and to use a high chair in order to avoid prosthesis dislocation.

Chapter 17. CONCLUSIONS:

1. The study of the results of kinematic and dynamic simulations performed on the virtual hip reveals the areas of focus of pressures, dislocations and deformations. This explains the occurrence of necrosis in the femoral head supporting area, oedema and the potential development of cysts in the cervix area (in the lower and posterior half) and the obstruction of the necrosis area.
2. The lesions of the cotyloid cavity develop later following the loss, by the femoral head, of its round shape.
3. MRI continues to be the election methods for the early diagnosis of AVNFH.
4. The presence on the scintigraphy of the "cold area", corroborated with the clinical situation is important in establishing the diagnosis and requires the use of MRI exam. The importance of the scintigraphy increases in the diagnosis of lesions in the "no contrast uptake hip".
5. The decompression drill carried out in stage 1 and 2 has an immediate antalgic effect. However, in the following months the antalgic effect lowers and after 3-4 years Harris score decreases under 65 points (failure) to over 65% of patients, and the lesions progress towards the stage 3-4.
6. The inter-trochanteric osteotomies are intended to bring in the supporting position a healthy area of the femoral head. 72 osteotomies were performed (66 flexion osteotomies and 6 varization osteotomies) observing the selection criteria according to Ficat and Steinberg. 2 years after the osteotomy good results have been obtained in 60% of patients (Harris score over 65 points), results that are also maintained in the following 6-7 years. 7-10 years after osteotomy Harris score decreased under 65 points and the radiological appearance damaged, which required another therapeutic solution.
7. The best results from the patients subjected to osteotomies have been obtained in stages 1-2. The inter-trochanteric osteotomies ensure a delay by 7-8 years of the reconstructive procedures.
8. 54 non-cemented bipolar prostheses were implanted in stages III-IV (Ficat or Steinberg), ensuring a quasinormal activity in 72% of patients over a period of 10 years. NBP is, therefore, a solution for delaying the implantation of total prostheses in these patients.

9. The total prosthesis was implanted in 107 patients with lesions in stage 4-6 (93 non-cemented total prostheses and 14 cemented total prostheses).
10. 10 years after the implantation of the non-cemented total prosthesis all patients have Harris score over 70 points.
11. The early diagnosis and the correct choice of surgical procedures are basic elements enabling to keep a functional joint over a period of 7-10 years, delaying reconstructive operations (arthroplasty).

Selective references :

1. Antonescu D, *La nécrose aseptique de la tête fémorale. Ethiopatogenie et diagnostic*, Louvain-la-Neuve, Conférence d'enseignement, 1998
2. Arlet J, *Nontraumatic avascular necrosis of the femoral head*, Clin. Orthop., 1992, 277, 12-21
3. Arlet J, Ficat R.P, Pujol M, Lartigue G, Latorzeff S, *Ischémie et nécrose de la tête fémorale après traumatisme sans fracture*. Rhumatologie (Aix-les-Bains), 1973, 25, 159..
4. Arnoldi CC, Lemperg RK, Linderholm H, *Immediate effects of osteotomy on the intramedullary pressure of the femoral head and neck in patients with degenerative osteoarthritis*. Acta Orthop. Scand. 1071, 42, 357.
5. Atsumi T, Kuroki Y, *Role of impairment of blood supply of the femoral head in the pathogenesis of idiopathic osteonecrosis*. Clin Orthop 1992, 277:22-30.
6. . Basett LW, Mirra JM, Cracchiolo A III, Gold RH, *Ischemic necrosis of the femoral head. Correlation of magnetic resonance imaging and histologic sections*. Clin Orthop 1987, 223:181-187.
7. Bombelli R, *Structure and function in normal and abnormal hips*, Springer, Berlin, New York, 1993.
8. Bordei P, Ulmeanu D, *Anatomia descriptivă a membrilor*, Ed Ex Ponto, Constanța, 2002, 314-320.
9. Campbell's *Arthroplasty of Hip* Operative Orthopaedics, T. Mosby, 1998, vol. 1, partea IX, 1213.
10. Cartier PH, *L'ostéotomie de varisation dans la nécrose idiopathique de la tête fémorale*. Thèse Médecine, Paris 1970.
11. D'Antonio J.A. et al, *Hydroxyapatite coated implants. Total hip arthroplasty in the young patients and patients with avascular necrosis*, Clin. Orthop., 1997, Nov.; (344); 124-38.
12. Dinulescu I., Marinca L., Marin L., Parvulescu V., Filip M. *Osteotomiile de bazin în tratamentul displaziilor acetabulare la adolescent și adult*, Rev. Ortop. Traumatol., 1994, vol. 4, nr. 1-2, 3-17.
13. Dinulescu I. – *Aseptic necrosis of the femoral head and its treatment*. European Instructional Course Lectures,. The British Editorial Society of Bone and Joint Surgery, London, 1995 Vol. II, 9-18.
14. Eftekhar N.S. *Principles of total hip arthroplasty*, Mosby Year Book, St. Louis, 1978.
15. Ficat R.P, Arlet J, Vidal, R, Ricci, A, Fournial, JC, *Résultats thérapeutiques du forage-biopsie dans les osteonecroses femoro-capitales primitives (100 cas)*. Rev. Rhum. 1971, 38, 269.
16. Ficat P, *Idiopathic bone necrosis of the femoral head. Early diagnosis and treatment*, JBJS 67-B, 3-9, 1985.

17. Ficat R.P., Arlet J. – *Ischemia and necrosis of bone*, Williams and Williams, Baltimore, London, 1980.
18. Ficat, P., Arlet, J – *Stade pré-radiologique de l'osteonecrose femoro-capitale. Possibilités diagnostiques et thérapeutiques*. Rev. Chir. Orthop. 1973, 59, suppl. 1, 26
19. Ficat, P., Arlet, J. *L'exploration fonctionnelle de la circulation intra-osseuse et ses applications*. Paris : Masson, 1977.
- 20 Floares G, *Unele opinii privind tratamentul osteonecrozei idiopatice a capului femural, în legătură cu 63 de cazuri operate*, Rev. Ortop. Traumat., 1992, vol. 2, nr. 2-3, 23-30.
21. Frankel ES, Urbaniak JR, *Osteonecrosis in Kelley's Textbook of Rheumatology*, 8th Edition, Saunders, 2008.
22. Gaucher A, *L'étiologie, le terrain biologique et la pathogénie de l'ostéonecrose aseptique de la tête fémorale chez l'adulte (à propos de 32 nouvelles observations)*, Ann. Med. Nancy, 1971, 10, 23..
23. Gardeniers JWM, ARCO committee on terminology and staging (report on the committee meeting at Santiago De Compostela). ARCO Newsletter 1993; 5:79-82.
24. Gray's Anatomy , Deacon House, London,1994.
25. Hauzeur JP, Pasteels JL, Schoutens A, et al., *The diagnostic value of magnetic resonance imaging in non-traumatic osteonecrosis of the femoral head*, J Bone Joint Surg Am 1989; 71-641-649.
26. Hungeford DS, Zizic TM, *Pathogenesis of ischemic necrosis of the femoral head in: The hip*, Hungeford DS, Proc. of the 11th meeting of the Hip Society, St. Louis, C. V. Mosby, 1983, 249-62.
27. Kim YM, Ahn JH, Kang HS, Kim HJ *Estimation of the extent of osteonecrosis of the femoral head using MRI*, J Bone Joint Surg Br.,1998;80:954-8.
28. Koo K-H, Kim R *Quantifying the extent of osteonecrosis of the femoral head. A new method using MRI*, J Bone Joint Surg Br.,1995;77:875-80.
29. Jaqueline, F, Rutishauer, E., *Idiopathic necrosis of the femoral head. Anatomopathological study*. In Idiopathic ischemic necrosis of the femoral head in adults, Edited by W.M. Zinn, G. Thieme Publishers, Stuttgart 1971, 34 ..
30. Lafforgue P, Dahan E, Chagaud C, Schlano A, Kasbarian M, Acquaviva P-C, *Early-stage avascular necrosis of the femoral head: MR imaging for prognosis in 31 cases with at least 2 years of follow-up*, Radiology, 1993;187:199-204.
31. Mitchell DG, Rao VM, Dalinka MK, Spritzer CE, Alavi A, Steinberg ME, Fallon M, Kressel HY, *Femoral head avascular necrosis: correlation of MR imaging, radiographic staging, radionuclide imaging, and clinical findings*, Radiology, 1987;162:709-15.
32. Morcher E.W., Dick W., Kernen V. – *Cementless fixation of polyethylene acetabular component in total hip arthroplasty*; Acta Orthop., 1992, 282, p. 53.
33. Papilian V, *Anatomia omului*, vol I Aparatul locomotor, ed V, Ed Didactică și Pedagogică, București, 1974, 146-151.
34. Plenck H Jr, Gstettner M, Grossschmidt K, Breitenseher M, Urban M, Hofmann S: *Magnetic resonance imaging and histology of repair in femoral head osteonecrosis*. Clin Orthop 2001, 386:42-53.
35. Pop, TS, *Studiul necrozei avasculare postcortizonice a capului femural*, lucrare de doctorat, 1997.

- 36.** Shimizu K, Morya H, Akita T, Sakomoto M, Suguro T, *Prediction of collapse with magnetic resonance imaging of avascular necrosis of the femoral head*, J. Bone Joint Surg. (Am.) 1994, 76A, 215-23.
- 37.** Steinberg M, Hayken JD, Steinberg DR, *A new method for evaluation and staging of avascular necrosis of the femoral head*. Bone circulation, Williams and Wilkins 1984.
- 38.** Stanescu C, *Etiopatogenia osteonecrozei aseptice atraumatice a capului femural la adult*, Teza de doctorat, Bucuresti, 1997.
- 39.** Stoica C. – *Locul osteotomiei in necroza atraumatica a capului femural*. Teza de doctorat, Bucuresti, 1997.
- 40.** Thomine JM, *L'arthroplastie par cupule ajustée pour nécrose de la tête fémorale*. Rev. Chir. Orthop. 1973, Suppl. 1, 61.
- 41.** Trueta J, Harrison MH, *The normal vascular anatomy of the femoral head in adult man*, J. Bone Joint Surg., 1953, 35B, 442-461.
- 42.** Turek, SL – Third Edition – J.B. Lippincott Company, Philadelphia, 1977, 994-1008.
- 43.** Vignon G, Falconet M, Chapuy P, *Osteonecroses aseptiques epiphysaires idiopathiques de l'adulte*. Encyclopédie médico-chirurgicale. Appareil locomoteur. 57 Cahier specialise, 1970, 41.
- 44.** Zienkiewicz OC, Taylor RL, *The Finite Element Method*. Fifth edition. Vol. I The Basis. Butterworth & Heinemann, Oxford 2000
- 45.** Zienkiewicz OC, Taylor RL, *The Finite Element Method*. Fifth edition. Vol. II Solid Mechanics. Butterworth & Heinemann, Oxford 2000
- 46.** Zienkiewicz OC, Taylor RL, *The Finite Element Method*. Fifth edition. Vol. III Fluid Dynamics. Butterworth & Heinemann, Oxford 2000