

UNIVERSITY OF MEDICINE AND PHARMACY CRAIOVA

PH. D. THESIS

- SUMMARY –

***ANGIOGENESIS IN PANCREATIC DUCTAL
ADENOCARCINOMA:
MORPHOMETRIC AND IMMUNOHISTOCHEMICAL STUDY***

SCIENTIFIC SUPERVISOR:

PROFESSOR TUDOREL CIUREA, M.D.,Ph.D.

PH. D. CANDIDATE :

ANCA BARĂU

CRAIOVA

2013

CONTENTS

INTRODUCTION	5
--------------------	---

GENERAL SECTION

1. ANGIOGENESIS	
1.1 ORIGIN OF BLOOD VESSELS.....	6
1.2 TYPES OF ANGIOGENESIS.....	9
1.3 POSTNATAL ADAPTATION.....	11
1.4 ANGIOGENESIS IN THE NEOPLASTIC PROCESS.....	12
1.5 CLINICAL APPLICATIONS.....	19
2. PANCREATIC DUCTAL ADENOCARCINOMA (PDAC)	
2.1 DEFINITION, EPIDEMIOLOGY, RISK FACTORS.....	26
2.2 TUMOR MARKERS FOR PDAC.....	29
2.3 TNM CLASSIFICATION, PDAC TUMOR STAGES.....	33
2.4 ANGIOGENESIS IN PDAC.....	35
2.5 HISTOLOGICAL FEATURES FOR PDAC.....	37
3. IMMUNOHISTOCHEMISTRY TECHNIQUES	
3.1 GENERAL ASPECTS.....	40
3.2 ANGIOGENIC MARKERS.....	42
4. MORPHOMETRY TECHNIQUES	
4.1 GENERAL ASPECTS.....	45
4.2 QUANTIFICATION OF MICROVASCULAR DENSITY.....	49

SPECIAL SECTION

5. TYPE OF STUDY AND OBJECTIVES.....	51
6. MATERIAL AND METHODS	
6.1 MATERIAL.....	53
6.2 METHODS	
6.2.1 IMMUNOHISTOCHEMICAL STUDY.....	57
6.2.2 MORPHOMETRY STUDY.....	60
6.3 STUDY VARIABLES AND STATISTICAL ANALYSIS.....	65
7. RESULTS.....	71
8. DISCUSSIONS.....	87
9. FINAL CONCLUSIONS.....	95
10. BIBLIOGRAPHY.....	97

KEY WORD: Pancreatic ductal adenocarcinoma, angiogenesis, microvessel density, CD 31 antibody, hot-spot method

INTRODUCTION

Pancreatic ductal adenocarcinoma is recognized as one of the most aggressive forms of malignancy and it ranks among the top five causes of death through cancer after gastric, breast, lung and prostate cancer. [75,76] At the time of diagnosis, approximately 85% of patients have advanced stage disease with local invasion or metastasis and cannot be submitted to surgery with curative intent. [77]

Pancreatic cancer has two special features. Firstly, this type of cancer is highly invasive and resistant to conventional chemotherapy and radiotherapy, and secondly, it produces a dense stroma, rich in collagen fibres, extracellular matrix proteins, fibroblasts and inflammatory cells termed desmoplastic reaction. [112] The first feature seems to be a consequence of the second, meaning that the mechanical barriers surrounding the tumor are one reason why pancreatic cancer is one of the most drug-resistant forms of cancer.

Fibrous matrix accumulates large amounts of hyaluronan increasing interstitial fluid pressure and constricting tumor vasculature. Under these circumstances it is difficult for any cancer drugs to diffuse from the blood into the tumor. [176] Dense stroma surrounding the tumor cells creates a special microenvironment characterized by hypoxia and nutrient deficiency. These conditions may lead to the selection of the most aggressive tumor cells. [175]

The main role in the formation and turnover of the stroma is assigned to the pancreatic stellate cells, which also appear to be responsible for the poor vascularization of pancreatic cancer. [128,129]

This study was financially supported by funds from the European Social Fund - Programul Operațional Sectorial Dezvoltarea Resurselor Umane 2007-2013, proiectul „Creșterea calității și vizibilității rezultatelor cercetării științifice a doctoranzilor cu frecvență prin acordarea de burse doctorale”, contract POSDRU/107/1.5/S/82705.

ANGIOGENESIS IN PANCREATIC DUCTAL ADENOCARCINOMA

Although angiogenesis is regarded as an essential factor for tumor growth, this process of formation and development of new capillaries from pre-existing vessels remains controversial in pancreatic ductal adenocarcinoma. [1-3]

Research studies for pancreatic tumor angiogenesis are limited. It is known that this type of neoplasia shows reduced neovascularization. [111,112] compared with other types of cancer, pancreatic ductal adenocarcinoma is less vascularized and perfused. [113]

In addition, vascularization of pancreatic ductal adenocarcinoma is lower compared to non-malignant pancreatic diseases such as chronic pancreatitis. [114] Besides the fact that angiogenesis is poorly expressed in pancreatic ductal adenocarcinoma, newly formed capillaries shows very high permeability facilitating the penetration of tumor cells in circulation. [115]

Angiogenesis measured as tumor microvessel density (MVD) has been shown to be associated with poor prognosis in several neoplasms such as rectal [177], breast [169,179,180], gastric [178] and lung cancer [181].

The literature data for pancreatic ductal adenocarcinoma are controversial. Although there are few positive reports dealing with pancreatic cancer [113,172,182,183], some studies have shown that prognosis in pancreatic cancer seems to be independent of angiogenesis [184].

Intratumoral hypoxia appears to be associated with tumor development, invasion and metastasis. [119,120]

TYPE OF STUDY AND OBJECTIVES

The purpose of this study was to evaluate angiogenesis in pancreatic ductal adenocarcinoma by morphometric analysis and computerized image. Small blood vessels density reflect tumor angiogenesis.

In our study, microvascular density is used as a marker of pancreatic tumor angiogenesis.

We examined microvascular density in pancreatic ductal adenocarcinoma cases (intratumoral and peritumoral areas) and also in cases of normal pancreatic tissue.

This study was conducted in Pathology Department of University Hospital - Valencia, Spain.

3 groups were formed:

-group 1 : tumoral pancreatic tissue (pancreatic ductal adenocarcinoma) **60 cases**

-group 2: peritumoral pancreatic tissue (peritumoral area of pancreatic ductal adenocarcinoma cases) **30 cases**

-group 3: normal pancreatic tissue (humans autopsy) **30 cases**

Main objectives of this study are:

1. Analysis of the main clinical and morphological parameters of pancreatic ductal adenocarcinoma:
 - Study of clinical parameters: sex, age, tumor topography
 - Study of morphological parameters: tumor size, histological form, tumor differentiation degree, vascular and perineural invasion, nodal involvement, tumor stage, presence or absence of distant metastasis.
2. Showing the statistically significant correlation between clinical and morphological parameters investigated.
3. Identify the type of vessels and their maturation in both cases – pancreatic ductal adenocarcinoma (intratumoral area and peritumoral area) and normal pancreatic tissue.

4. Angiogenic phenotype study according to histological differentiation degree.
5. Comparative analysis of blood vessel density and distribution in the intratumoral area, peritumoral area and normal pancreatic tissue.

MATERIAL AND METHODS

A. MATERIAL

Paraffin-embedded tissue blocks from 60 surgically resected human pancreatic adenocarcinomas were selected for this study. All patients underwent surgery in the University Clinical Hospital of Valencia.

Cephalic duodenopancreatectomy was performed in 44 cases, splenopancreatectomy in 13 cases and total pancreatectomy in 3 cases.

As a control, we used 30 cases of normal pancreatic tissue from autopsy material.

B. METHODS

- **HISTOLOGICAL TECHNIQUE**

Surgical resection parts were processed in the laboratory of pathology department of the University Hospital of Valencia being fixed in formaldehyde and then included in paraffin blocks. From paraffin blocks were made 2-3 μm thick sections using Beecher Instrument equipment (Silver Springs, MD, USA).

Histological sections were stained with Hematoxylin-Eosin and the most representative parts for each case were selected (tumoral, peritumoral or normal), without necrosis, fibrosis or other pathological changes that could cause results change.

- IMMUNOHISTOCHEMICAL TECHNIQUE

60 cases of pancreatic ductal adenocarcinoma and 30 normal pancreatic tissue specimens were analyzed immunohistochemically for evidence of blood vessels.

Endothelial cells were marked using the automated DAKO Autostainer Universal Staining System. Immunostaining with the endothelial cell marker CD31 was performed following an avidin-biotin immunoperoxidase procedure (Avidin Biotinylated enzyme Complex).

The primary monoclonal antibody was used at a dilution of 1:50 (DAKO Envision, Santa Cruz Biotechnology), previously treated by autoclave incubation for 3 minutes at 1.5 atmospheres with citrate buffer pH 6.1.

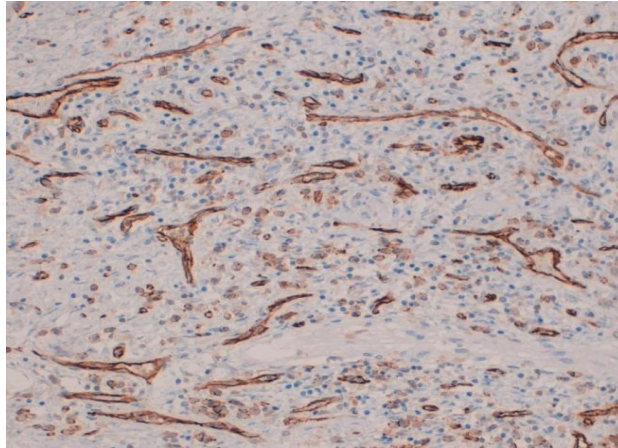
After washing the samples three times with Tris Buffered Saline (TBS), release reaction was made by adding DAB chromogen (3,3'diaminobenzidine) as a chromogen staining substrate for 5 minutes. Tissue sections were counterstained with hematoxylin.

- MORPHOMETRIC ANALYSIS

To quantify vessel neof ormation we used hot spot method according to Weidner method. [169] After CD31 staining, each case was evaluated in order to select the area with the highest vascularization. For this purpose a Leica DMD 108 digital microimaging device was used.

Brown-stained cell groups clearly distinguishable from the background were counted as one vessel. All groups of cells positive for CD31 endothelial cell marker but without an evident lumen, were considered as undifferentiated vessels. Vascular hot spots were identified at a low optical power using a 4x and 10x objective. Five equal areas of high vascularization were photographed with a 20x objective. **(fig.46)**

Fig. 46 *PDAC. Intratumoral area. CD31. X200*



Measurements were performed using the Image Pro-Plus 6.0 Image Analysis System (Media-Cybernetics). Any artifacts occurring in the samples were removed manually.

Vessels were grouped according to caliber into the following categories:

-Capillaries: D. Max. 8-15 μm

-Arterioles: D. Max. 15-50 μm

-Small Arteries: D. Max. 50-200 μm

Range **0-600 μm^2** was considered for **area**.

STATISTICAL ANALYSIS

Statistical analysis was performed using the SPSS version 19. The following tests were applied: Standard Error Bars (a 95% confidence interval), Student's t-test and ANOVA test.

The Student's independent samples t-test and ANOVA were used to compare means in groups. All data are presented as mean \pm standard deviation. A difference of $p < 0.05$ between the groups was considered to be statistically significant.

RESULTS

A. HISTOPATHOLOGICAL STUDY OF PANCREATIC DUCTAL ADENOCARCINOMA

For each of the 60 cases of pancreatic ductal adenocarcinoma, medical records data were used to analyse: patient age, sex, type of surgery performed, tumor location, tumor grade, tumor differentiation, lymph node metastasis, distant metastasis.

In this study, the highest incidence of pancreatic ductal adenocarcinoma by age was observed in patients over 60 years (75% of the group).

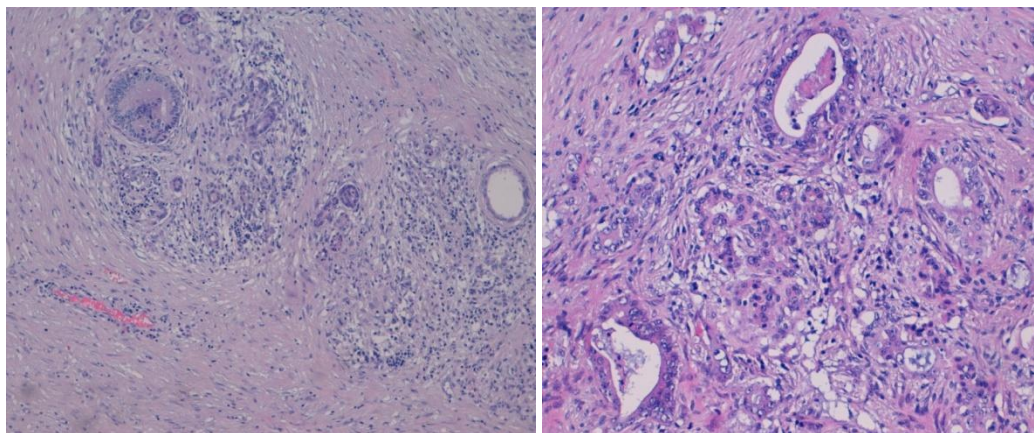
Patients distribution by sex showed a higher prevalence in men. (63,3% of the group).

Type of surgery performed was mainly dictated by tumor location. In our study, the primary tumor location was the cephalic location (48 cases) so surgery performed was cephalic duodenopancreatectomy.

Analyzing tumor progression according to *AJCC 7th ed. 2010*, 34 cases had stage III – tumor spread beyond the pancreas without celiac trunk or mesenteric artery invasion.

We noticed that most pancreatic ductal adenocarcinoma were moderately differentiated tumors (38 cases- more than half of the studied cases). (**fig. 43**)

Fig. 43 *Moderately differentiated pancreatic ductal adenocarcinoma. H-E.X200*



(Glandular structures similar to pancreatic ducts surrounded by a fibrous stroma.

Intraductal mucin.)

Other parameters like lymph node metastasis, vascular and perineural invasion, and distant metastasis were analyzed.

66,6% of cases had nodal involvement, 78,3% of cases had vascular and perineural invasion and only 1 case had distant metastasis.

B. IMMUNOHISTOCHEMICAL STUDY OF PANCREATIC DUCTAL ADENOCARCINOMA

We analyzed microvascular density using CD31 immunostaining.

This study shows a higher microvascular density in group I compared with group II and III. (fig.49, 50)

This study demonstrates a higher MVD in intratumoral areas than in peritumoral areas and normal pancreatic tissue.

The total number of vessels, the number of capillaries and number of arterioles were higher in tumor samples than in peritumoral and normal samples (p value between 0.000 and 0.003 using ANOVA and Student's t-test). (fig.51)

Fig.49,50. Total number of vessels and number of capillaries in all 3 studied groups (tumoral, peritumoral and normal)

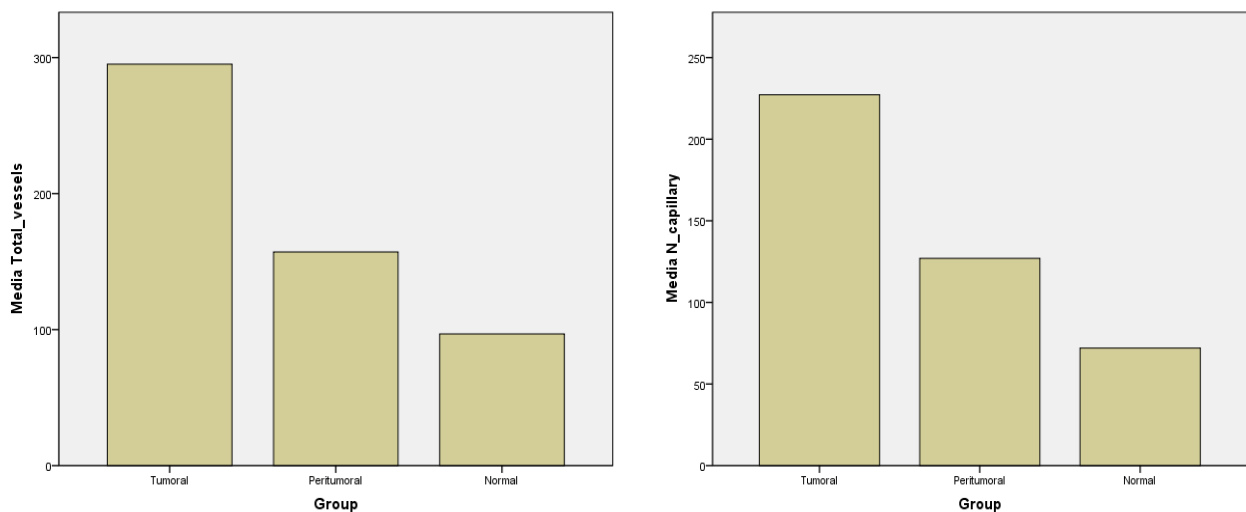


Fig. 51. Total number of vessels, number of capillaries and number of arterioles in all 3 studied groups (tumoral, peritumoral and normal)

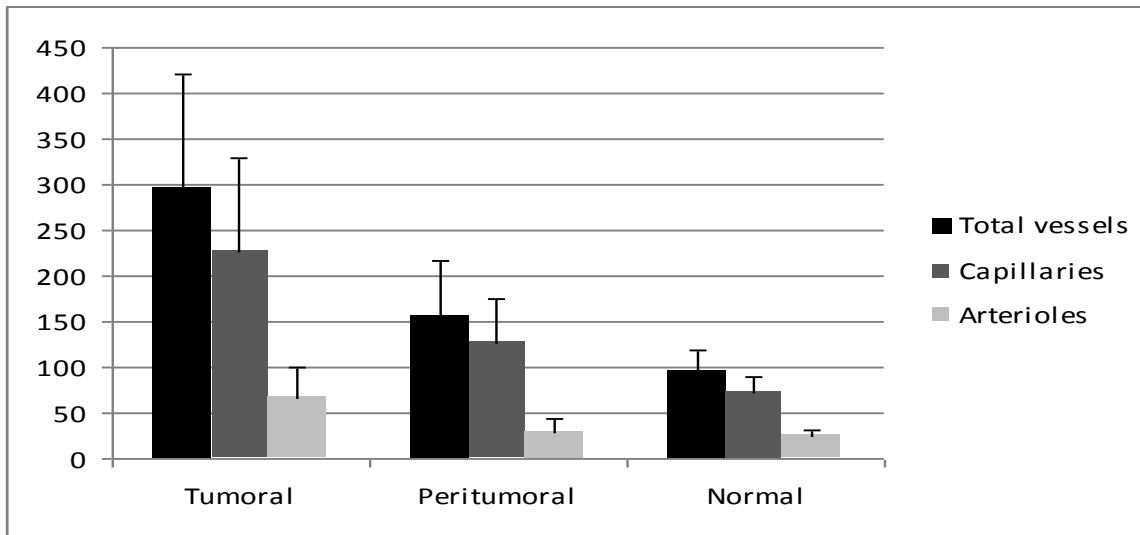


Table nr.11 shows the differences between all 3 studied groups in terms of total vessels, number of capillaries and arterioles.

Table 11. Mean values for vascular parameters in relation to groups

Vascular Parameter	N (n=30)	PT (n=30)	T (n=60)	N vs. PT*	N vs. T**	PT vs. T***
Total Vessels	96.77 ± 21.358	157.07 ± 58.918	295.20 ± 126.172	P<0.000	P<0.000	P<0.000
No. of Capillary	72.00 ± 18.155	127.03 ± 48.868	227.23 ± 101.057	P<0.000	P<0.000	P<0.003
No. of Arterioles	24.43 ± 6.240	28.67 ± 15.379	67.28 ± 32.861	P<0.000	P<0.000	P<0.002

*Abbreviations: N = Normal Pancreatic Tissue, PT = Peritumoral Area, T = TumorArea, * Statistical comparison between normal pancreatic tissue and peritumoral area,** Statistical comparison between normal pancreatic tissue and intratumoral area, ***Statistical comparison between peritumoral and intratumoral area.*

Correlation between vascular parameters and clinicopathological features

A positive association was found between **total number of vessels and tumor differentiation (p<0.05)**.

More precisely, on comparing the **total number of vessels between well differentiated and poorly differentiated cases of PDAC**, the **p** value was **0.015**.

A **p** value of **0.032** was found when comparing **moderately differentiated** with **poorly differentiated tumors**, but no statistically significant differences were found between well differentiated and moderately differentiated tumors.

In addition, no significant relationship was found between vascular parameters and other clinicopathological characteristics including age, sex, tumor location, tumor grade, vascular and perineural invasion, lymph node metastasis and distant metastasis.

DISCUSSION

Since Folkman proposed the theory of tumor angiogenesis and noted that tumor cells cannot develop in the absence of neovascularization, research on this subject has increased rapidly. The angiogenic process has been widely studied in different neoplasms and much information has been collected, illustrated by the numerous reviews that summarize important data about mechanisms of angiogenesis. [170,171]

The study of angiogenesis seems to be of great value in providing the key to a fuller understanding of the tumor process, as well as offering a starting point for developing new therapeutic strategies.

This interest is especially high in pancreatic carcinoma, as this is one of the most aggressive types of cancer, highly invasive, rapidly reaching the stage of metastasis. However, studies of pancreatic adenocarcinoma angiogenesis are fewer than those reported in other types of neoplasms.

Several studies have shown that intratumoral microvessel density has prognostic relevance in pancreatic cancer [113,172,182,183], while others indicate the contrary. [184]

It has also been shown that intratumoral microvascular density values are higher in pancreatic tumors with hot spot areas in the neoplastic parenchyma than in those with hot spots only in the desmoplastic stroma of the tumor. [188]

Our study aimed to assess microvascular density in a comparative manner using representative pancreatic adenocarcinoma samples for the intratumoral and peritumoral areas. We also wanted to find the difference between microvessels in tumor and normal pancreatic tissue.

We faced difficulties in choosing the endothelial cell marker and vessel counting method. There is no perfect marker for endothelial cells, the three most commonly used endothelial markers being CD31, CD34 and von Willebrand factor (vWF), each having its own advantages and disadvantages. We opted for CD31, as recommended by Vermeulen et al. [185]

In this study we chose to perform a computer image analysis. The great advantage of using a computer system is the fact that it allows the analysis of other parameters such as diameter and area. To increase the accuracy of the study, any artifacts occurring in the samples were removed manually.

We found a significant difference in MVD between intratumoral areas, peritumoral areas and normal pancreatic tissue.

In fact, the largest number of newly formed small vessels was seen in intratumoral areas, supporting the existence of an angiogenic process. In addition, peritumoral areas had a greater number of vessels compared with normal tissue, demonstrating that the tumor extends its influence to the surrounding tissue. These findings support the strong angiogenicity of PDAC and open up the possibility for the use of antiangiogenic drugs as a targeted therapy in controlling this highly aggressive cancer.

Finally, the many discrepancies in terms of case selection criteria, staining techniques and endothelial markers used, and also in the vessel counting methods applied, make it difficult to compare results between the previously published studies. Thus a standardization of MVD assessment is necessary.

Similar data were limited, so this work represents a novelty in the field of pancreatic tumor angiogenesis.

FINAL CONCLUSIONS

- Pancreatic ductal adenocarcinoma represents an important factor of morbidity and mortality, ranking among the top five causes of death through cancer after gastric, breast, lung and prostate cancer. Given the reserved prognosis of patients diagnosed mostly in advanced stages of disease, development of new anticancer therapies represents a major challenge for the medical world. Tumor angiogenesis studies could provide the key to new therapeutic strategies development.
- Our study has allowed a detailed analysis of microvascular density in a comparative manner using representative pancreatic adenocarcinoma samples for the intratumoral and peritumoral areas. We also wanted to find the difference between microvessels in tumor and normal pancreatic tissue. In addition was made a correlation between vascular parameters and the main clinical and histopathological characteristics of the studied cases.
- Histopathological study showed predominant distribution of pancreatic ductal adenocarcinoma cases in patients over 60 years and also demonstrated the predominance of this neoplasia in male population. The tumor was most commonly located on pancreatic cephalic region, progression stage was III with vascular and perineural invasion without distant metastasis. Histologically, the majority of pancreatic ductal adenocarcinoma cases were moderately differentiated.
- Immunohistochemical study demonstrates a significant difference in microvascular density between intratumoral areas, peritumoral areas and normal pancreatic tissue. In fact, the largest number of newly formed small vessels was seen in intratumoral areas, supporting the existence of an angiogenic process. In addition, peritumoral areas had a greater number of vessels compared with normal tissue, demonstrating that the tumor extends its influence to the surrounding tissue.
- Statistical analysis showed a positive association between total number of vessels and tumor differentiation ($p < 0.05$). More precisely, on comparing the total number of vessels between well differentiated and poorly differentiated cases of PDAC, the p value was 0.015. A p value of 0.032 was found when comparing moderately

differentiated with poorly differentiated tumors, but no statistically significant differences were found between well differentiated and moderately differentiated tumors. In addition, no significant relationship was found between vascular parameters and other clinicopathological characteristics including age, sex, tumor location, tumor grade, vascular and perineural invasion, lymph node metastasis and distant metastasis.

SELECTIVE BIBLIOGRAPHY

1. Burri P, Hlushchuk R, et al. Intussusceptive angiogenesis: its emergence, its characteristics, and its significance. *Developmental dynamics: an official publication of the American Association of Anatomists* 2004;231(3):474-88.
2. Carmeliet P. Mechanisms of angiogenesis and arteriogenesis. *Nature Med* 2000;6:389-395.
3. Carmeliet P. Developmental biology. One cell, two fates. *Nature* 2000;408:43-45.
75. Ryu JK, Hong SM, Karikari CA et al. Aberrant MicroRNA-155 expression is an early event in the multistep progression of pancreatic adenocarcinoma. *Pancreatology* 2010; 10:66-73.
76. Kesavan Y, Giovannucci E, Fuchs CS et al. A prospective study of magnesium and iron intake and pancreatic cancer in men. *Am J Epidemiol.* 2010;171:233-24.
77. Jemal A, Siegel R, Ward E, et al. Cancer statistics, 2008. *CA Cancer J Clin.* 2008;58(2):71-96.
111. Koong AC, Mehta VK, Le QT, et al. Pancreatic tumors show high levels of hypoxia. *Int. J. Radiat. Oncol. Biol. Phys.* 2000;48:919-922.
112. Apte MV, Park S, Phillips PA, et al. Desmoplastic reaction in pancreatic cancer: Role of pancreatic stellate cells. *Pancreas* 2004; 29:179-187.
113. Ueda T, Oda T, Kinoshita T, et al. Neovascularization in pancreatic ductal adenocarcinoma: Microvessel count analysis, comparison with non-cancerous regions and other types of carcinomas. *Oncol Rep* 2002;9:239-45.
114. Rzepko R, Jaskiewicz K, Klimkowska M, et al. Microvascular density in chronic pancreatitis and pancreatic ductal adenocarcinoma. *Folia Histochem Cytobiol* 2003;41:237-9.
115. Folkman J. Fundamental concepts of the angiogenic process. *Curr Mol Med* 2003;3:643-51.
119. Brizel DM, Scully SP, Harrelson JM et al. Tumor oxygenation predicts for the likelihood of distant metastases in human soft tissue sarcoma. *Cancer Res.* 1996;56:941-943.
120. Hockel M, Schlenger K, Aral B, et al. Association between tumor hypoxia and malignant progression in advanced cancer of the uterine cervix. *Cancer Res.* 1996;56:4509-4515.
128. Masamune A, Shimosegawa T. Signal transduction in pancreatic stellate cells. *J Gastroenterol* 2009;44:249-60.
129. Erkan M, Reiser-Erkan C, Michalski CW, et al. Cancer stellate-cells interactions perpetuate the hypoxia fibrosis cycle in pancreatic ductal adenocarcinoma. *Neoplasia* 2009;11:497-508.
169. Weidner N. Current pathologic methods for measuring intratumoral microvessel density with breast carcinoma and other solid tumors. *Breast Cancer, Res Treat.* 1995;36:169-180
170. Weidner N. Angiogenesis as a predictor of clinical outcome in cancer patients. *Hum Pathol* 2003;31:403-405.
171. Weidner N. Tumor vascularity: what does it tell us about the growth and spread of cancer? In: D'Amore PA, Voest E, eds. *Tumor angiogenesis and microcirculation*, New York, NY: Marcel Dekker; 2001: 465-486

172. Ikeda N, Adachi M, Taki T, et al. Prognostic significance of angiogenesis in human pancreatic cancer. *British Journal of Cancer* 1999;79:1553-1563
175. Vasseur S, Tomasini R, Tournaire R, et al. Hypoxia induced tumor metabolic switch contributes to pancreatic cancer aggressiveness. *Cancers* 2010;2:2138-2152.
176. Whatcott CJ, Han H, Posner RG, et al. Targeting the tumor microenvironment in cancer: Why Hyaluronidase Deserves a Second Look. *Cancer Discovery* 2011;1:291-296
177. Svagzdys S, Lesauskaite V, Pavalkis D, et al. Microvessel density as a new prognostic marker after radiotherapy in rectal cancer. *BMC Cancer* 2009; 9:95
178. Hong-Chuan Zhao, Rong Qin, Xiao-Xin Chen, et al. Microvessel density is a prognostic marker of human gastric cancer. *World J Gastroenterol* 2006;12:7598-7603.
179. Ravazoula P, Hatjikondi O, Maragoudakis M, et al. Angiogenesis and metastatic potential in breast carcinoma. *The Breast* 1996;5:418-421
180. Uzzan B, Nicolas P, Cucherat M, et al. Microvessel density as a prognostic factor in women with breast cancer: a systematic review of the literature and meta-analysis. *Cancer Res* 2004;64:2941-2955
181. Han H, Silverman JF, Santucci TS, et al. Vascular Endothelial Growth Factor Expression in Stage I Non-Small Cell Lung Cancer Correlates With Neoangiogenesis and a Poor Prognosis. *Annals of Surgical Oncology* 2001;8:72-79
182. Takagi K, Takada T, Amano H. A high peripheral microvessel density count correlates with a poor prognosis in pancreatic cancer. *J Gastroenterol* 2005;40:402-8
183. Karademir S, Sokmen S, Terzi C, et al. Tumor angiogenesis as a prognostic predictor in pancreatic cancer. *J HepatobiliaryPancreatSurg* 2000;7:489-95.
184. Van der Zee JA, Van Eijck CH, Hop WC, et al. Angiogenesis: a prognostic determinant in pancreatic cancer? *Eur J Cancer* 2011;47:2576-84
185. Vermeulen PB, Gasparini G, Fox SB, et al. Quantification of angiogenesis in solid human tumors: in international consensus on the methodology and criteria of evaluation. *Eur J Cancer* 1996;32:2474-84

Curriculum vitae

SURNAME: BARĂU
FIRST NAME: ANCA
DATE OF BIRTH: 27 Noiembrie 1985
NATIONALITY: Română
ADDRESS: Str. Ștefan Odobleja, Bl. a15, et. 3, Ap. 12, Craiova, Dolj,
Romania
PHONE: +40741034807
E-MAIL: anca_barau@yahoo.com
PROFFESION: Resident Physician Internal Medicine

EDUCATION

2000 – 2004: National College Elena Cuza Craiova, Natural Sciences Department.

Diploma seria T, nr. 0379179, 2004.

2004-2010: General Medicine Faculty – U.M.F. Craiova

2008: 1-31 august – Tanta University Hospital – General surgery - Tanta - **Egypt**

2009: 1-28 august – Faculty Hospital Kramare – General Surgery – Bratislava - **Slovakia**

October 2010 : Ph. D. Candidate – Internal Medicine

2011-present: Residency Internal Medicine, Emergency Clinical Hospital no.1 Craiova

2012: 1 aprilie- 30 septembrie – Hospital Clinico Universitario Valencia, Spania

(Pathology Department)

SCIENTIFIC WORKS

- „Tumor markers for pancreatic adenocarcinoma”- Current Health Sciences Journal, Volume 39, Supplement 7, 2013 – first author
- „High microvessel density in pancreatic ductal adenocarcinoma is associated with high grade”- Virchows Archiv, The European Journal of Pathology, Volum 462, Numărul 5, 2013 – first author
- „Why pancreatic cancer is highly invasive and drug-resistant?”- Current Health Journal, Volume 39, Supplement 3, 2013 – first author
- „Particularități clinice și paraclinice la pacienții cu boală hepatică alcoolică”- Revista de Medicină Internă, nr.6 , 2011 – first author
(Clinical and paraclinical features in patients with alcoholic liver disease)

PAPERS PUBLISHED IN SUMMARY

- “Benign cysts of the upper splenic pole – laparoscopic management in 2 cases” MEDIS 2010 – Timișoara
- “Comparative study of systemic bronchitis inflammation in patients with severe and very severe COPD with or without alfa1-antitrypsin” CIMSC 2008 – Craiova
- “Materialele sintetice in cura eventratiilor postoperatorii” MARSIENSIS 2008 – Tg. Mures
- ‘The main cutaneous manifestations at the patients with chronic B hepatitis’ ICMS 2007 – Sofia – Bulgaria
- ‘The incidence of the vasculitis syndromes at the patients with B chronic Hepatitis’ CONGERSSIS 2007 – Iași
- ‘Manifestările cutanate frecvent întâlnite le pacienții cu hepatită cronică B’ Conferința națională pentru studenți și tineri medici 2007- Craiova
(Cutaneous manifestation commonly found in patients with chronic hepatitis B)
- “Studiul circulației venoase bronhice la plămânul de om” Congresul Național pentru Studenți și Tineri Medici 2006 – București
(Study of bronchial circulation in the human lung)

PARTICIPATIONS IN SCIENTIFIC WORKS

27.04.2012- “101 Reunio de la Societat de Patologia de la Comunitat Valenciana”

- Xativa, Spania

19-21.05.2010 – International Medical Congress for Students and Young Doctors

“MedEspera”, 3th edition Chişinău - Republica Moldova

22-25.04.2010 – International congress for medical students and young doctors, 14th
edition – Timişoara

20-23.11.2008 – Craiova International Student’s Conference, 10th edition – Craiova

17-20.04.2008 – International Scientific Congress for students, young doctors and
Pharmacists, “MARSIIENSIS” 12th edition- Tg. Mures

10-13.05.2007 – International congress of Medical Sciences for students and young
Doctors, 6th edition , – Sofia, Bulgaria

29.03-1.04.2007 – International congress for medical students and young doctors,
4th edition – Iaşi

15-18.03.2007 - National Conference for students and young doctors, 8th edition Craiova

23-26.11.2006 – National Congress for students and young doctors, 10th edition, Bucureşti